

HGPS (Hutchinson-Gilford -Progeria syndrome)

Suryanarayanan R¹, Niladri Das², Vishal Sawant³, Alpana Santosh Kondekar⁴, Santosh Kondekar^{5*}

^{1,2}Post Graduate Resident, ³Assistant Professor, ^{4,5}Associate Professor, Dept. of Pediatrics, TN Medical College and Nair Hospital, Mumbai, Maharashtra, India

***Corresponding Author: Santosh Kondekar**

Email: drkondekar@gmail.com

Abstract

Eight year old male child, born of non- consanguinity presented with complaints of irritability and drowsiness with history of left sided weakness. He was stunted and had hypertension at presentation. Also he had dysmorphic features and skin manifestations with skeletal deformities and muscle wasting. Motor examination revealed muscle wasting with increased tone and decreased power on both sides. In Hutchinson -Gilford -Progeria syndrome, large and small vessel occlusive disease due to atherosclerosis can occur. CVA and Stroke can also result due to cerebral infarction or carotid artery occlusion. In our case, patient had MRI brain suggestive of areas of acute infarct and also evidence of chronic infarct and MR angiography suggestive of vasculopathic changes. Patient was started antihypertensives and tab aspirin and gradually his sensorium improved, BP got normalized and planned discharge and advised regular follow up and physiotherapy.

Keywords: Progeria, Stroke, HGPS.

Introduction

Hutcinson -Gilford -Progeria syndrome is a rare, fatal, autosomal dominant premature aging disease. HGPS was first described at the end of the 19th century by Jonathan Hutchinson and Hastings Gilford. Incidence is 1 in 40,00,000 live births with no gender, ethnic or regional bias. It is caused by single base mutation in LMNA, results in production of mutant lamin A protein called progerin. Progerin is found in increased concentration in skin, vascular wall of normal older compared to younger individuals. Children develop progressive atherosclerosis and die of heart attacks or strokes at median age of 14.5 yr, most often between ages 5 and 20 yr.

Case Report

8 year old male child, born of non- consanguinity presented with complaints of irritability and drowsiness for 4 days of duration. He had also history of left sided weakness, unable to sit, stand along with the present illness. At presentation he was drowsy with GCS of 14/15 and BP-160/110(>99th percentile) with mild tachycardia and maintained saturation 95% in room air. Anthropometry showed Weight of 9 kg (below 3rd centile) , Height of 98cm(below 3rd centile) , Weight for Height below 3rd SD. Head to toe examination revealed sparse, lusterless, hypopigmented hair with madrosis. He had facial dysmorphism in form of partially closed eyes, beaked nose, retrognathia, dental malocclusion with poor oral hygiene. Skin was wrinkled, hyperpigmented, and tightened appearance with loss of subcutaneous fat. He had Pectus carinatum,

harrison's sulcus with Joints stiffness present at knee, hip and neck and general muscle wasting. Motor examination revealed showed muscle wasting with increased tone and decreased power on both sides. Deep tendon reflexes 2 + with left plantar being extensor and no sensory deficit. There were no meningeal signs or no signs of cerebellar involvement.

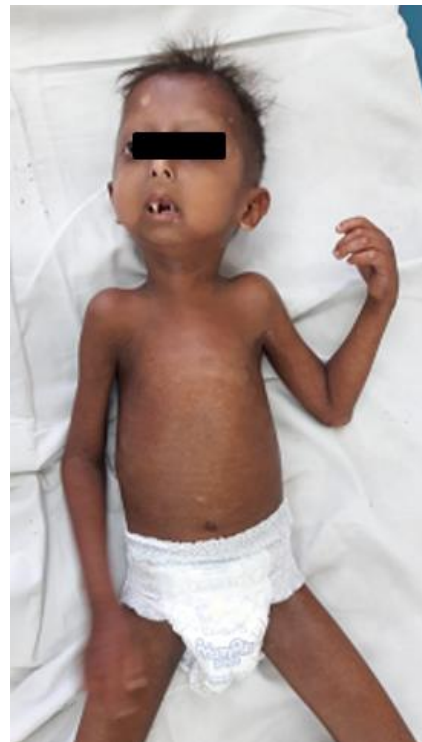

Fig. 1:

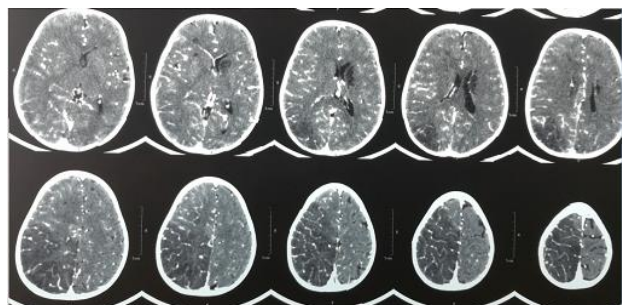


Fig. 2: CT scan brain with contrast

Discussion

In Hutchinson-Gilford-Progeria syndrome, skin and hair changes are the initial signs that usually manifest. Within the first few years of life severe failure to thrive ensues with generalised lipoatrophy and apparent wasting of limbs with weight deficit is more than height deficit can be seen. Delayed tooth eruption and persistence of primary teeth throughout the life may present, with crowded teeth and micrognathia. Also they are prone for corneal dryness and ulcers as they sleep partial eye open. Skeletal dysplasia and facial dysmorphism are another findings in these individuals. Early signs in x-ray reveal acro osteolysis of distal phalanges, distal clavicular resorption and thin, tapered ribs. Other skeletal deformities include facial disproportion, narrowed nasal bridge, retrognathia, pyriform chest, knee ankle contracture, hip dysplasia, hip dislocation with bone age and growth plates being normal, but severe abnormality in structural geometry. Large and small vessel occlusive disease due to atherosclerosis, a primary vasculopathy or vascular stiffening can manifest and Hypertension, angina, cardiomegaly, metabolic syndrome and heart failure being end-stage events. CVA and Stroke can also result due to cerebral infarction or carotid artery occlusion. Liver, kidney, thyroid, immune, gastrointestinal and neurologic systems and intellect (normal for age) are apparently normally functioning systems.

He was shifted to intensive care after CT imaging being done. His CT brain showed Diffuse and few discrete hypodensity in right fronto-parieto-occipital region with loss of grey-white matter differentiation and Gliotic changes in left caudate nucleus, anterior limb of internal capsule likely suggestive of old vascular infarct. Fundus examination and CSF analysis were normal. He was started on nifedipine as BP was above 99th percentile. He required one packed red cell transfusion and tab aspirin was started because of

ischemic insult. His coagulation studies were normal. His Iron studies revealed nutritional anemia and sickling test being negative. MRI brain showed areas of acute infarct in right fronto-parieto-occipital, right temporal and left frontal region with gliotic area noted in left caudate nucleus suggestive of chronic infarct and MR angiography suggestive of vasculopathic changes. Carotid and renal artery doppler was performed which reported as normal. 2D Echo showed mild MR, grade 2 AR, rest normal study. He was shifted to ward as sensorium improved, BP normalized and started to accept food orally. Physiotherapy continued and planned discharge on tab aspirin and amlodipine and was advised regular follow up on opd basis.

Source of Funding

None.

Conflict of Interest

None.

References

1. Russo-Menna I, Arancibia C. The Hutchinson-Gilford Progeria Syndrome: a case report. *Minerva Anestesiologica* 2010;76:151-4. [PubMed] [Google Scholar]
2. The Progeria Handbook: A Guide for Families and Health Care Providers of Children with Progeria. Accessed January 25, 2011. Available from: http://www.progeriaresearch.org/patient_care.html.
3. Cleveland RH, Gordon LB, Kleinman ME, Miller DT, Gordon CM, Snyder BD, Nazarian A, Giobbie-Hurder A, Neuberg D, Kieran MW. A prospective study of radiographic manifestations in Hutchinson-Gilford progeria syndrome. *Pediatr Radiol*. 2012;42:1089-1098. [PMC free article] [PubMed] [Google Scholar]
4. Gordon CM, Gordon LB, Snyder BD, Nazarian A, Quinn N, Huh S et al, Hutchinson-Gilford progeria is a skeletal dysplasia. *J Bone Miner Res*. 2011;26:1670-9. [PMC free article] [PubMed] [Google Scholar]
5. Zhang H, Chen X, Guo Y, Liang J, Tang L, Yu H et al, Hutchinson-Gilford progeria syndrome: report of 2 cases and a novel LMNA mutation of HGPS in China. *J Am Acad Dermatol*. 2013;69:e175-e6. [PubMed] [Google Scholar]
6. Chen CP, Lin SP, Lin DS, Liu YP, Hsu LJ, Wang W et al. Clinical imaging findings in a girl with Hutchinson-Gilford progeria syndrome. *Genet Couns*. 2012;23:1-7. [PubMed] [Google Scholar]
7. rarediseases.org/rare-diseases/hutchinson-gilford-progeria

How to cite: Suryanarayanan R, Das N, Sawant V, Kondekar AS, Kondekar S. HGPS (Hutchinson-Gilford-Progeria syndrome). *IP J Surg Allied Sci* 2020;2(2):48-9.