



Case Report

Inter thenar skin sparing carpal tunnel release- role of incisions and endoscope - A case report

Narendra.S. Mashalkar^{1,*}

¹Dept. of Plastic Surgery and Burns, St. John's Medical College, Bengaluru, Karnataka, India



ARTICLE INFO

Article history:

Received 29-03-2022

Accepted 22-04-2022

Available online 31-05-2022

Keywords:

Carpal tunnel
Endoscopic assisted
Inter thenar space
Incisions

ABSTRACT

Endoscope in plastic surgery has played a role, wherever minimal scarring is required. An attempt to decrease the length of scar is one of the priorities of a surgeon, as this brings down the chance of scarring, pain and associated morbidity, with decreased hospital stay. Hand is an organ with intricate anatomy and many vital structures are densely packed in hand. This makes the available space scarce for another instrument to add into the hand.

Hence endoscopic intervention in hand is negligible. The margin of error also remains negligible in hand, as it would compromise on the function of hand, which is an absolute necessity.

Aesthetic appearance of hand is not as important as function; nevertheless if possible, one should also consider giving an aesthetic scar with good function of hand and these criteria will be the goal for any hand surgeon.

This is an Open Access (OA) journal, and articles are distributed under the terms of the [Creative Commons Attribution-NonCommercial-ShareAlike 4.0 License](https://creativecommons.org/licenses/by-nc-sa/4.0/), which allows others to remix, tweak, and build upon the work non-commercially, as long as appropriate credit is given and the new creations are licensed under the identical terms.

For reprints contact: reprint@ipinnovative.com

1. Introduction

Carpal tunnel syndrome is a very common disease¹ affecting the motor nerves and hence the function of hand, intervention at the appropriate stage will help in restoring the function of hand. Surgical treatment of this has been done with open release from time immemorial and¹ has given excellent results. With the advent of endoscopic procedures, it is tempting to use endoscope, as this has various advantages seen when done in other regions of human body. Applying the same principles of minimal invasive techniques will certainly help the patient, but the extent to which we can perform this surgery with additional instruments in such a compact area without damaging the nerves and vessels has to be determined.

2. Case History

A 30 yr old female presented to us with bilateral tingling and numbness in the thumb, index and middle finger with worsening pain after flexion of wrist joint since 3 yrs. She had no co morbidities. She was counseled about the nature of disease and treatment, consent was given to operate on the right hand. Fitness for surgery was obtained and surgery performed.

2.1. Surgical technique

1. After the preoperative markings, (Figure 1) initial incision of 2cms was made at the distal wrist crease transversely.
2. Palmaris longus tendon was identified and all dissection was carried out ulnar to this tendon.
3. Dissection was done deep to PL [Palmaris longus] and a tunnel was identified and created distally all along the inter-thenar crease.

* Corresponding author.

E-mail address: plasticnaren2005@yahoo.co.in (N. S. Mashalkar).

4. Hegars dilator was used to widen the tunnel. The tunnel created was 4.5 cms long and it stopped at the mid palmar crease.
5. A second incision was done at the mid palmar crease transversely about 2 cms and palmar aponeurosis was identified and cut. Distal margin of the TCL [Transverse Carpal Ligament] was identified and the tunnel created was identified by rail road technique (Figure 2).
6. Endoscope 30*, 4 mm was introduced from proximal entry and TCL undersurface was identified.
7. As we do not have the standard endoscope blade assembly instrument, we cut the TCL starting from the proximal to distal by open method with inter-thenar sparing skin and subcutaneous incision, clearly visualizing the TCL all along the length at the inter-thenar space.
8. The above dissection was inclined onto the ulnar side and we could not visualize the median nerve into the tunnel.
9. After completely releasing the TCL which will feel like a give way sensation and the inter thenar space will be softer when compared to pre op palpation.
10. Endoscope was introduced from the proximal incision and the cut TCL was visualized, it was cut all along (Figure 3).
11. Fibrous bands at the wrist were cut with the proximal incision and this completes the TCL cut with endoscopic and palpatory confirmation.
12. Incision were closed with 5/0 monofilament and a crepe bandage given with a bulky dressing underneath.
13. Post operative course was uneventful, without any iatrogenic neurological injury and patient had significant improvement in decline of pre existing neurological symptoms after 12 weeks of post operative period.

3. Discussion

The need to shift from standard carpal tunnel release to endoscopic assisted release seems natural for a surgeon, as early recovery and minimal scar seems possible with this technique, however newer techniques have added disadvantages of a learning curve, complication rates being higher in the initial surgeries, clear visualization of the vital structures may not be possible, difficulty in orientation to endoscopic instruments. In the present era of availability of literature on the net and presence of many recorded surgeries of previously performed endoscopic surgical techniques for carpal tunnel release, it gives an idea of the ease of performing this procedure for a given surgeon and hence to minimize the complications.² We have shifted to minimal invasive surgery for carpal tunnel release to avoid scar on the inter-thenar space, which has

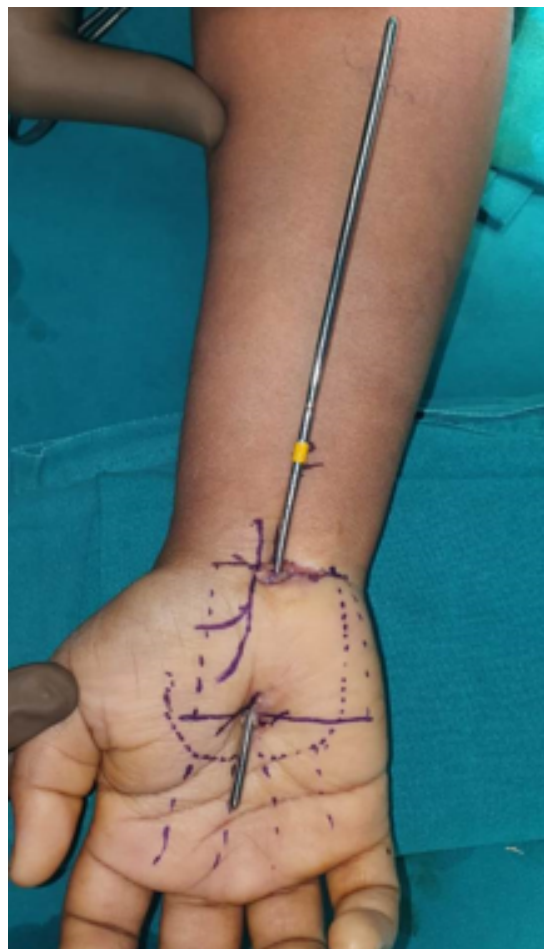


Fig. 1: Intra operative view of skin sparing tunneling.

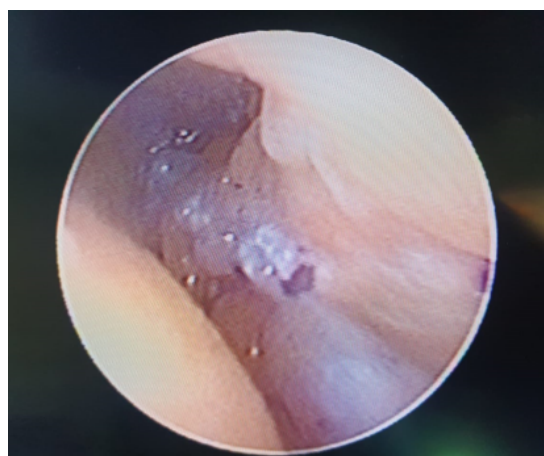

Fig. 2: Endoscopic view of cut TCL.

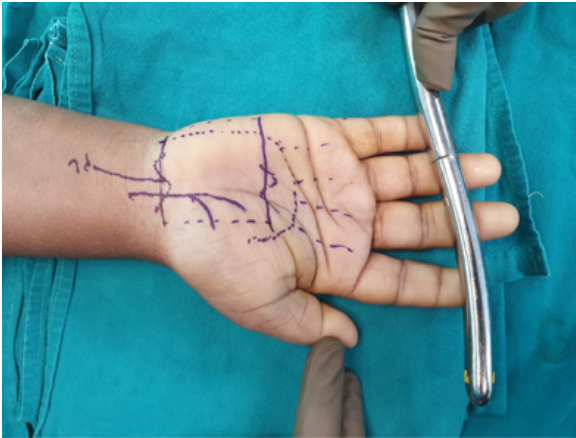


Fig. 3: Preoperative image of hand with markings.

been complained by many patients about forming a thick band of scar significant enough to assume by patients, that the scar band might be a reason for compression, even though compression caused by transverse carpal ligament is released. Our incision was placed at distal wrist crease and mid palmar transverse crease, hence avoiding the inter-thenar space. Various modified incision have been adopted in ECTR [endoscopic carpal tunnel release], endoscopic assisted carpal tunnel release, but few surgeons have actually placed a small inter- thenar vertical incision.^{1,3} The most important step is to identify and create a tunnel below the transverse carpal ligament; we approached and created the tunnel from the proximal site at wrist which has been applied by many authors.^{3,4}

Our distal incision was at the mid palmar level and the tunneling was done keeping both the proximal and distal transverse carpal ligament margins in view. We have visualized the entire transverse carpal ligament with the endoscope, due to paucity of standard ECTR instruments, division of the transverse carpal ligament was achieved by visualizing the transverse carpal ligament under magnification and incising the transverse carpal ligament from proximal to distal and vice versa, sparing an inter thenar skin incision, keeping the dissection fully under magnification. Standard ECTR with the endoscope blade assembly system have been done by various authors avoiding the inter-thenar space.^{1,5} We could not visualize the median nerve with the endoscopic lens as has been seen and quoted in literature by various authors.^{4,5} But we believe that staying in the right anatomical site and plane will generally keep the complications at minimal level as thorough knowledge of hand anatomy is essential to keep vital structures safe. We used our 30 degree 4 mm endoscope to confirm our completion of transverse carpal ligament cut and also to visualize if we have accidentally injured the palmar arch or nerve, we did this diagnostic endoscopic examination after we released the tourniquet

and hemostasis achieved as has been described in literature. There are various other techniques used for carpal tunnel release by using ultrasound guided and endoscopic either fully by specialized endoscopic instruments or modified by combination of both open and endoscopic approach.⁶ Our patient had no complications of infection or neuro vascular injury, literature quotes about increasing incidence of neuro vascular injuries by ECTR.^{2,6} but we certainly believe that poor visualization of nerve in ECTR stands a chance of neuro vascular injury. Early relief of symptoms were remarkable in our patient, however long term benefits of this method needs to be evaluated as literature quotes similar reversal of pathological changes in nerve by both open and ECTR techniques.⁵

4. Conclusion

Modified incisions with careful and adequate tunneling at the right anatomical location may be used safely for carpal tunnel release to avoid scarring the inter-thenar space and endoscope may be used as a supplement diagnostic tool for visualization and confirming the completeness of cut of transverse carpal ligament without injuring the vital structures at the wrist.

5. Abbreviations

1. TCL- Transverse carpal ligament
2. ECTR- Endoscopic carpal tunnel release

6. Source of Funding

None.

7. Conflict of Interest

None.

References

1. Malhotra R, Kiran EK, Dua A, Mallinath SG, Bhan S. Endoscopic versus open carpal tunnel release: A short-term comparative study. *Indian J Orthop.* 2007;41(1):57–61. doi:10.4103/0019-5413.30527.
2. Boeckstyns ME, Sorensen AI. Does endoscopic carpal tunnel release have a higher rate of complications than open carpal tunnel release? An analysis of published series. *J Hand Surg Br.* 1999;24(1):9–15. doi:10.1016/S0266-7681(99)90009-8.
3. Hegazy I, Montaser MG, Wahab MA. Endoscopic assisted carpal tunnel release through a limited transverse wrist incision. *Azhar Assuit Med J.* 2007;3(1):149–56.
4. Pennino R, Tavin E. Endoscopic-assisted carpal tunnel release: a coupling of endoscopic and open techniques. *Ann Plast Surg.* 1996;36(5):458–61. doi:10.1097/0000637-199605000-00003.
5. Oh WT, Kang HJ, Koh IH, Jang JY, Choi YR. Morphologic change of nerve and symptom relief are similar after mini-incision and endoscopic carpal tunnel release: a randomized trial. *BMC Musculoskelet Disord.* 2017;18(1):65. doi:10.1186/s12891-017-1438-z.
6. Ohuchi H, Hattori S, Shinga K, Ichikawa K, Yamada S. Ultrasound-Assisted Endoscopic Carpal Tunnel Release. *Arthrosc Tech.* 2016;5(3):483–7. doi:10.1016/j.eats.2016.01.035.

Author biography

Narendra.S. Mashalkar, Associate Professor

Cite this article: Mashalkar NS. Inter thenar skin sparing carpal tunnel release- role of incisions and endoscope - A case report. *IP J Surg Allied Sci* 2022;4(2):63-66.