



Short Communication

Role of guidelines in scar management

Marenika Manisekaran¹, Ravi Kumar Chittoria^{1,*}, Jacob Antony Chakaith¹

¹Dept. of Plastic Surgery, Jawaharlal Institute of Postgraduate Medical Education and Research, Puducherry, India



ARTICLE INFO

Article history:

Received 25-05-2022

Accepted 28-05-2022

Available online 31-05-2022

Keywords:

Low level laser therapy

Vancouver scar score

ABSTRACT

Scar can be defined as a fault or blemish resulting from wound, sore or burn. Hypertrophic scars and keloids are caused by chronic inflammation in the reticular dermis. Here we described our experience by using algorithms for treatment of scar.

This is an Open Access (OA) journal, and articles are distributed under the terms of the [Creative Commons Attribution-NonCommercial-ShareAlike 4.0 License](https://creativecommons.org/licenses/by-nc-sa/4.0/), which allows others to remix, tweak, and build upon the work non-commercially, as long as appropriate credit is given and the new creations are licensed under the identical terms.

For reprints contact: reprint@ipinnovative.com

1. Introduction

Scar can be defined as a fault or blemish resulting from wound, sore or burn.¹ Hypertrophic scars and keloids are caused by chronic inflammation in the reticular dermis.² Initially, deprodone propionate (a stronger steroid) plaster prevent and treat hypertrophic scars and keloids very effectively. Second, surgical methods have been optimized for each body region, so it improves cosmetic and functional outcome, safety, and recurrence rates. Third, the postoperative radiotherapy protocol have been fine-tuned, making it safer while remaining equally effective.³ In our study we used algorithms for treatment of scar.

2. Materials and Methods

The study was carried out in a tertiary care hospital in South India after receiving approval from departmental ethical committee. The subject was a 40 years old male patient who undergone fasciotomy and debridement over the right foot and leg following necrotising fasciitis. Patient was management with Split skin graft following which he developed hypertrophic scar.

There are a many tools available for scar assessment. The most important features which should be assessed are: colour, vascularity, light reflection, texture, contour, pliability, height, distortion, relation to the relaxed skin tension lines (RSTL) relation with important landmarks in the area of the body. Vancouver scar scale before starting scar management -10 .Video dermatoscopy done to assess the scar.(Figures 1 and 2)

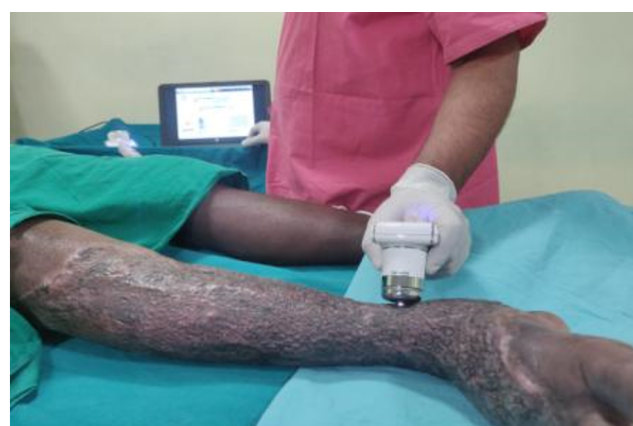

Fig. 1: Videodermoscopy assessment of scar

* Corresponding author.

E-mail address: drchittoria@yahoo.com (R. K. Chittoria).

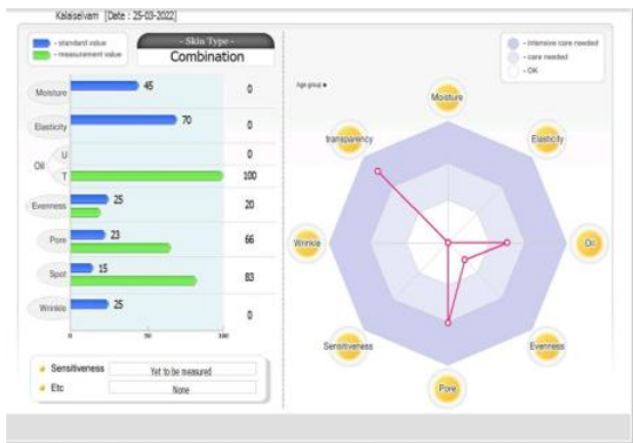


Fig. 2: Result for Videodermatometry

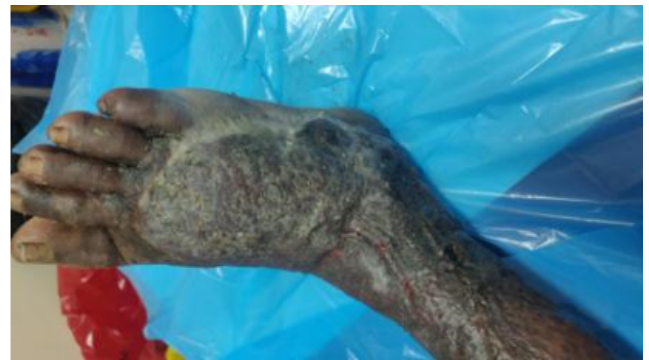

Fig. 5: Maceration of skin post scar management

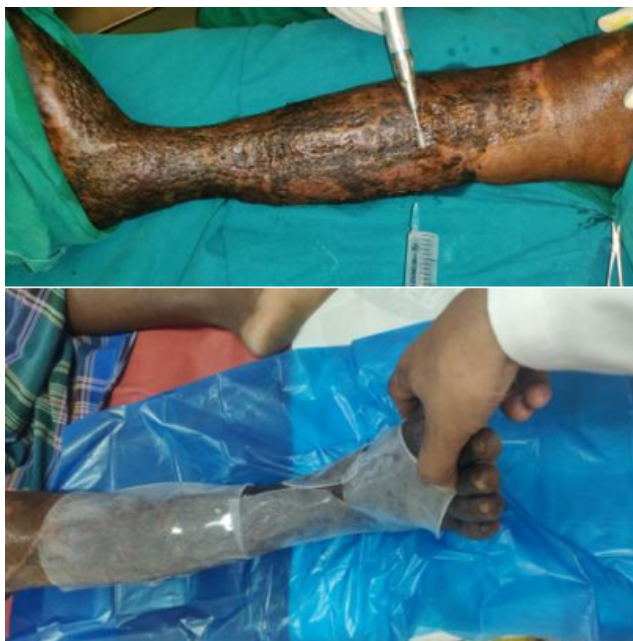

Fig. 3: Microdermabrasion



Fig. 6: Onion extract

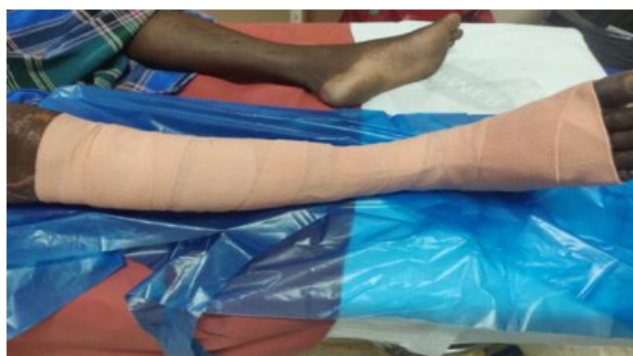

Fig. 4: Compression garment

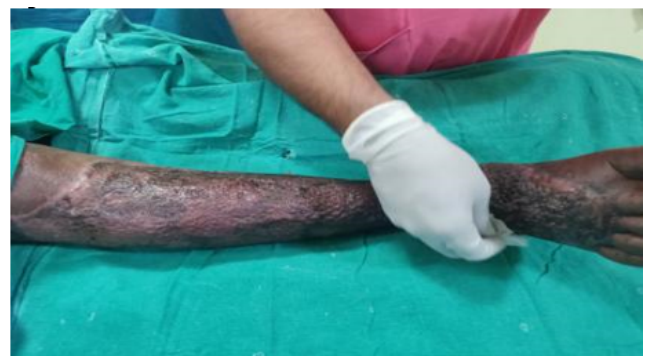

Fig. 7: Topical application of onion extract

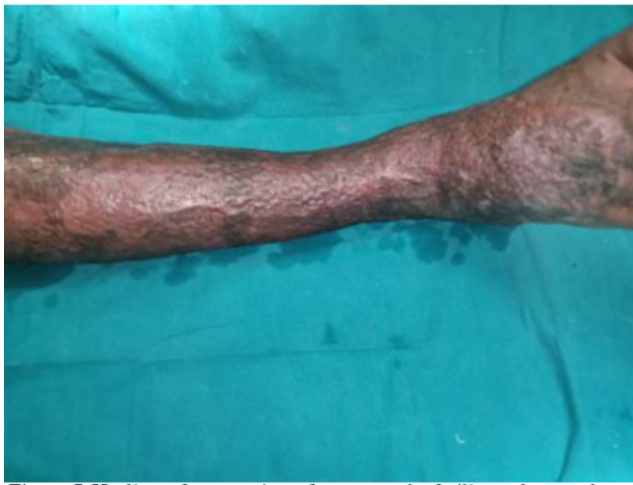

Fig. 8: Healing of maceration after removal of silicon sheet and compression garments. Application of Silver ointment and antibiotics

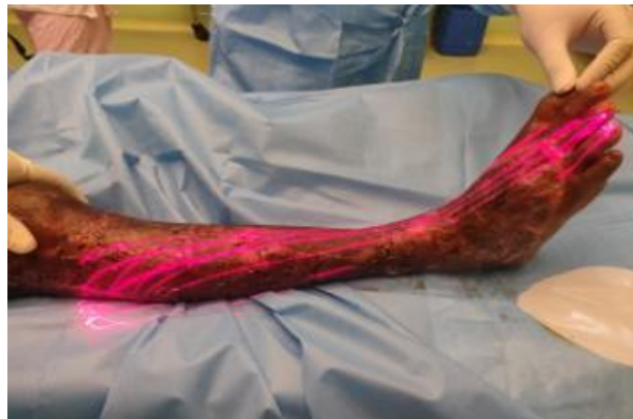

Fig. 9: Low level laser

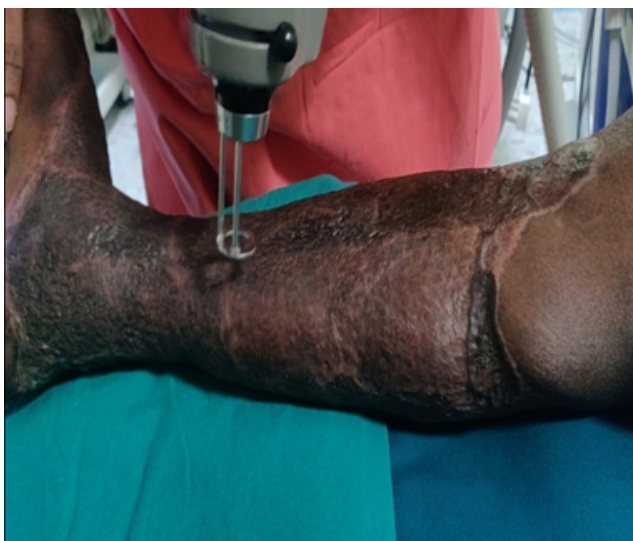

Fig. 10: High level laser

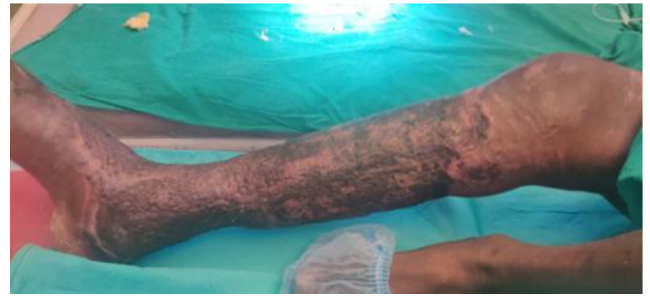

Fig. 11: After scar management

The scar was managed with coconut oil massage, microdermabrasion, silicone sheet application, compression garment.(Figures 3, 4 and 5) Maceration of skin noted for which hydrojet debridement, silver wash and cream application done(Figure 6).Topical onion extract application was done for scar(Figures 7 and 8). He undergone LLLT and high level laser therapy for scar management (Figures 8 and 9).At time of discharge score 7/13.(Figure 10)

3. Discussion

Scar control is complicated and difficult for a variety of reasons. The exact patho-physiology of scar formation is unknown, but several elements are thought to play a role, including the degree of tension across the wound's margins and the rate at which cells grow. Variable systems exist to assess changes in scar appearance, but theoretical models to evaluate current therapy are lacking. As a result, the amount of valuable data generated from prospective randomized research has been limited. Scar prevention and treatment can, however, be accomplished through a variety of methods.

Collagen remodeling it takes around 12-18 months for the scar to mature and gain tensile strength of 70-80% of uninjured skin. Immature scars are prone to hypertrophy and give poor results after scar revision.² Adjunct treatments like use of silicone sheet can be given during this period. Early intervention is needed it is wiser to do it only after 8-12 weeks in adults and 6 months in children smaller than 7 years of age. In our study we used various modalities of treatment for scar management as follow. Silicone gel sheets-Beneficial in inhibiting hypertrophic scar formation , are thought to shrink scars by increasing hydration and local skin temperature beneath the occlusive membrane . Silicone gel sheets are administered as soon as two weeks following a surgery in patients with predisposed factors for hypertrophic scarring.² Compression therapy improves wound healing by local vasoconstriction over post inflammatory burns area.15-25 mm HG improves burn and hypertrophic scar thickness,erythema and hardness.² Wound healing associates with initial inflammation that normally slowly wanes. At this point, massage may promote

mature scarring. However, in patients with risk factors, inflammation rises rather than subsides. Because massage stretches the scar, it could induce and worsen hypertrophic scars and keloids. Thus, scar massage in high-risk patients should be avoided.³ Onion extract has fibroblast-inhibiting characteristics, which lower fibroproliferative activity and ECM synthesis while enhancing MMP-1 expression.⁴ Onion extracts influence scar formation by inhibiting inflammatory processes, fibroblast proliferation, and fibroblast synthesising capacity. In the case of excessive scar formation in HTSs and keloid scars, onion extract has antiproliferative actions that suppress fibroblast proliferation and reduce scar size.⁵ Insufficient oxygen delivery can cause difficulties in wounds, preventing the usual healing process. Increased oxygen delivery to wounds especially necrotic ones like diabetic ulcer, will hasten the healing process. It has been demonstrated that LLLT can aid to remove hypoxia and ischemia in tissue that has been caused by vascular blockage.

4. Conclusion

In our study, guideline based algorithms for the treatment of scar was useful. VSS score improved from 10 to 7. Patients with treated hypertrophic scars should be taught on scar maintenance and monitored throughout time.

5. Source of Funding

None.

6. Conflict of Interest


None.

References

1. Garg S, Dahiya N, Gupta S. Surgical Scar Revision: An Overview. *J Cutan Aesthet Surg*. 2014;7(1):3–3.
2. Ogawa R. The Most Current Algorithms for the Treatment and Prevention of Hypertrophic Scars and Keloids: A 2020 Update of the Algorithms Published 10 Years Ago. *Plastic Recon Surg*. 2022;149(1):79–94.
3. Teng SC. Use of negative pressure wound therapy in burn patients. *Int Wound J*. 2016;13(3):15–8.
4. Vrijman C, Vandrooge AM, Limpens J, Bos JD, Van Der Veen JPW, Spuls PI, et al. Laser and intense pulsed light therapy for the treatment of hypertrophic scars: a systematic review. *Bri J Dermatol*. 2011;165(5):934–42.
5. Rabello FB, Souza CD, Farina JA. Update on hypertrophic scar treatment. *Clinics*. 2014;69(8):565–73.

Author biography

Marenika Manisekaran, Senior Resident

Ravi Kumar Chittoria, Professor  <https://orcid.org/0000-0002-4637-7503>

Jacob Antony Chakaith, Senior Resident

Cite this article: Manisekaran M, Chittoria RK, Chakaith JA. Role of guidelines in scar management. *IP J Surg Allied Sci* 2022;4(2):70-73.