



Case Report

Association of gastric duplication cyst with isolated oesophageal atresia and one additional floating rib — A rare presentation

Aditya Pratap Singh¹, Dinesh Kumar Barolia^{2,*}, Harsha Vinod Bathia³, Vipal H Parmar⁴, Bhavana Asit Mehta⁵, Shraddha Mehta⁶

¹Dept. of Paediatric Surgery, Bhagwan Mahavir Hospital, Pali, Rajasthan, India

²Dept. of Paediatric Surgery, Jawaharlal Nehru Medical College., Ajmer, Rajasthan, India

³Dept. of Anaesthesia, Bhagwan Mahavir Hospital, Pali, Rajasthan, India

⁴Consultant Histopathologist at Neuberg Supratech References Laboratories, Ahmedabad, Gujarat, India

⁵Neuberg Supratech Reference Laboratory, Ahmedabad, Gujarat, India

⁶Dept. of Pathology, Bhagwan Mahavir Hospital, Pali, Rajasthan, India



ARTICLE INFO

Article history:

Received 08-12-2022

Accepted 17-12-2022

Available online 23-01-2023

Keywords:

Duplication cyst

Enteric duplication

Gastric duplication cyst

Oesophageal atresia

and Floating rib

ABSTRACT

A gastric duplication cyst is not a common anomaly of the alimentary tract. The most common site of alimentary tract duplication is the ileum. We found a non-communicating gastric duplication cyst, along with the greater curvature of the stomach during feeding gastrostomy for isolated Oesophageal atresia. We are reporting a gastric duplication cyst associated with isolated Oesophageal atresia and left side one additional floating rib. This is the third case report of gastric duplication cyst with Oesophageal atresia in English literature.

This is an Open Access (OA) journal, and articles are distributed under the terms of the [Creative Commons Attribution-NonCommercial-ShareAlike 4.0 License](https://creativecommons.org/licenses/by-nc-sa/4.0/), which allows others to remix, tweak, and build upon the work non-commercially, as long as appropriate credit is given and the new creations are licensed under the identical terms.

For reprints contact: reprint@ipinnovative.com

1. Introduction

Enteric duplication cyst is a rare entity. It can be found from mouth to rectum throughout the gastrointestinal tract. Ileum is the most common(30-35%) site of enteric duplication. Incidence of duplication in alimentary tract is 20% in oesophagus, 13% in colon, 10% in jejunum, 7% in stomach and 5% in duodenum.^{1,2} Most common presentation of Gastric duplication is non-communicating, cystic pattern. Most common site of gastric duplication is along the greater curvature of stomach.³ Gastric duplication represents 4-7% in whole enteric duplication. Near about 67% of gastric duplication are diagnosed up to the first birthday of baby.⁴ Here, we are reporting a case of cystic duplication of stomach association with isolated Oesophageal atresia and one additional floating rib. This is an extremely rare

association.

2. Case Report

An 1850 gram male child, delivered at full-term, vaginal without any obstetric complication in hospital. He had complaints of frothing from mouth and regurgitation of feed. He was referred to our hospital after optimization. He was admitted here. On clinical examination baby has upper abdominal fullness and excessive frothing from mouth. Red rubber catheter (10 french) introduced to rule out Oesophageal atresia but could not be negotiated beyond 10 cm. There was no pallor and no jaundice and no other visible abnormality. Babygram with red rubber catheter showed gas less abdomen except one irregular shape area at left hypochondriac region. There was one additional floating rib present left side (Figure 2). Other skeletal system was normal. Our differential diagnosis was isolated Oesophageal

* Corresponding author.

E-mail address: dbaroliarmt@gmail.com (D. K. Barolia).

atresia with pyloric atresia. USG abdomen showed two heterogeneous cystic structures with thick walls (3.8x3.0 cm and 1.7x1.6 cm) were noted at left hypochondriac region. These lesions were abutting and compressing the stomach. Spleen and kidney were seen separately and normal. These findings were concluded foregut duplication or extra lobar pulmonary sequestration. After getting routine blood reports baby was taken for surgery on live day second. Baby was operated under general anaesthesia with endotracheal intubation in supine position and bolster beneath the both shoulders to make slight extension of neck. After painting and draping, mid line upper abdominal incision was given. Stomach was delivered through wound. There was a palpable cystic swelling at middle of greater curvature of stomach (Figure 1). This cystic swelling was excised and stomach was repaired and feeding gastrostomy done. Cyst was not communicating with stomach cavity. Abdominal wall repaired and feeding gastrostomy tube was fixed from abdominal wall. Left cervical esophagostomy was made to drain out the saliva from oral cavity. Excised cystic swelling was sent for histopathological examination. Histopathology of specimen was showing gastric mucosa with muscle layers, which proposed the gastric duplication cyst.

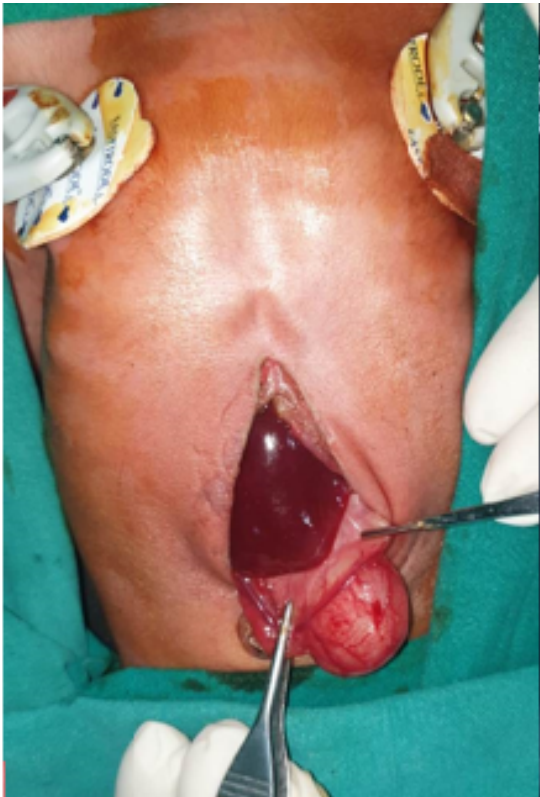

Fig. 1: Showed duplication cyst along the greater curvature.

Sham feeding was started on post-operative day two. Feeding through gastrostomy tube was started on seventh post-operative day. Baby tolerated feed through gastrostomy

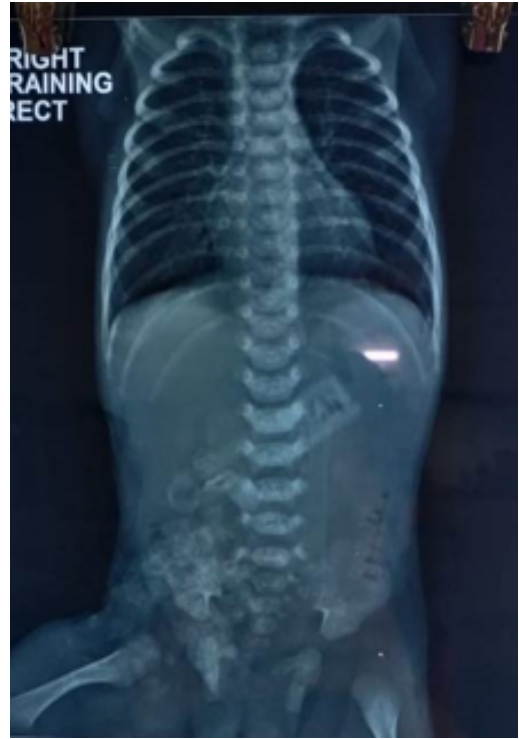

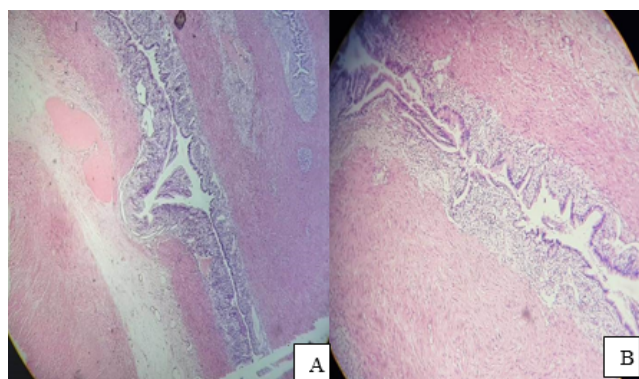
Fig. 2: X-ray showed gasless abdomen indicating isolated oesophageal atresia and one additional floating rib left side.

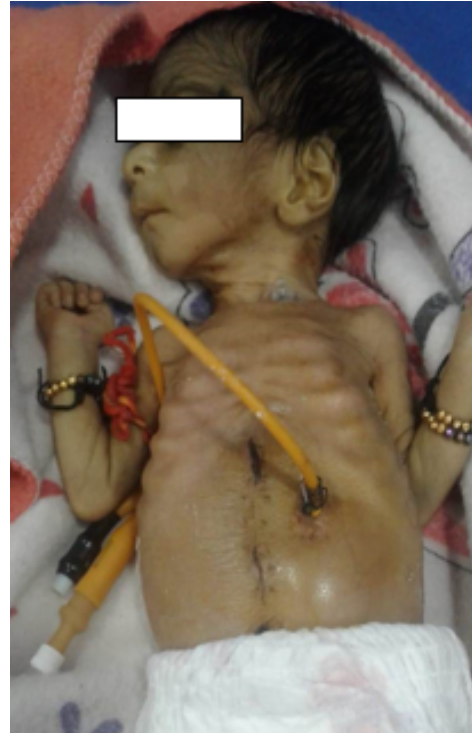

Fig. 3: Showing follow up photograph of baby having feeding gastrostomy tube and cervical oesophagostomy.

Table 1: Table1- table containing reported cases of gastric duplication associated with oesophageal atresia

S. No.	Author name with presenting year	Site of gastric duplication	Associated Oesophageal atresia (EA)	Histopathological finding	Gender
1	Hemalatha et al. 1980 ⁵	Tubular duplication along the greater curvature	EA distal TEF	Pyloric type gastric mucosa with aberrant pancreatic tissue with smooth muscle tissues	
2	Piplani R.et al.2018 ⁶	Cystic duplication of greater curvature of the stomach	EA distal TEF	Gastric lining including all layers of the gastrointestinal tract with Heterotopic pancreatic tissue	Male
3	Reporting case Dr.Dinesh Kumar Barolia et. al.]	Cystic duplication of greater curvature of the stomach	Isolated EA	All smooth muscle layers and containing gastric mucosa	Male

**Fig. 4:** H & E stained histopathology slides of excised duplication cyst-showed gastric mucosa and muscle layers.

tube and his journey was uneventful after surgery in six month follow up (Figure 3).

Showing follow up photograph of baby having feeding gastrostomy tube and cervical oesophagostomy.

3. Discussion

Gastric duplication is a rare entity. Greater curvature is the most common site of gastric duplication. Antrum is the dominant site of greater curvature. Cystic form is the major presentation.^{4,7,8} In our case duplication cyst was present along the greater curvature at antrum non-communicating.

Cardinal features of enteric duplication are (a) developed smooth muscle coat (b) lining epithelium comparable to intestinal mucosa (c) sharing common blood supply (d) communicating or non-communicating with alimentary tract. Gastric duplication can present with palpable swelling in upper abdomen. Some time it may present with recurrent non-bilious vomiting.^{4,9} Gastric duplication cyst can be treated by drainage in jejunum mostly in non-communicating cyst. Formation of common cavity of cyst and stomach can be done in communicating cyst. Complete excision of duplication cyst and repair is the treatment of

choice.¹⁰

Spataru R.I. et al. (2015) tabulated all the Reported cases of esophageal atresia associated with foregut duplications in their article. Only seventeen cases of esophageal atresia associated with foregut duplications were reported. Oesophageal duplication was the common site of fore gut duplication. Gastric duplication was less common in association with oesophageal atresia.¹¹ Only one case was reported till 2015. This first case was reported by Hemalatha et al. in 1980. They reported tubular gastric duplication along greater curvature associated with oesophageal atresia and tracheoesophageal fistula (EA-TEF).⁵

Second case of gastric duplication with oesophageal atresia was reported by Piplani R. et al. (2018). The gastric duplication was cystic along greater curvature associated with oesophageal atresia and tracheoesophageal fistula (EA-TEF).⁶

Here we are reporting the third case of gastric duplication along the greater curvature associated with oesophageal atresia without tracheoesophageal fistula (EA without TEF). This is the case of gastric duplication with associated with oesophageal atresia without tracheoesophageal fistula (isolated oesophageal atresia) and additional one rib.

4. Conclusion

Gastric duplication with association of oesophageal atresia is an extremely rare entity. To the best of our knowledge, this is the first case report in English literature of isolated Oesophageal atresia with association of gastric duplication cyst and one additional floating rib.

5. Source of Funding

None.

6. Conflict of Interest


None.

References

1. Berrocal T, Hidalgo P, Gutiérrez J, Pablo D, Rodríguez-Lemos L. Imagenradiológica de lasduplicaciones del tubodigestivo. *Radiología*. 2004;46(5):282–92.
2. Sharma S, Yadav AK, Mandal AK, Zaheer S, Yadav D, Samie A. Enteric duplication cysts in children: a Clinicopathological dilemma. *J Clin Diagn Res*. 2015;9(8):8–11.
3. Lund DP, Coran AG, Adzick NS, Krummel TM, Laberge JM, Shamberger RC. Alimentary tract duplications. Elsevier Saunders; 2012. p. 1155–65.
4. Johnston J, Wheatley GH, Sayed HF, Marsh WB, Ellison EC, Bloomston M. Gastric duplication cysts expressing carcinoembryonic antigen mimicking cystic pancreatic neoplasms in two adults. *Am Surg*. 2008;74(1):91–4.
5. Hemalatha V, Batcup G, Brereton RJ. Intrathoracic foregut cyst (foregut duplication) associated with Oesophageal atresia. *J Pediatr Surg*. 1980;15(2):178–80.
6. Piplani R, Acharya SK, Bagga D. Gastric duplication cyst associated with Oesophageal atresia and anorectal malformations: A rareassociation. *J Neonatal Surg*. 2018;7(3):36. doi:10.21699/jns.v7i3.750.
7. Murakami S, Isozaki H, Shou T, Sakai K, Toyota H. Foregut duplication cyst of the stomach with pseudostratified columnar ciliated epithelium. *Pathol Int*. 2008;58(3):187–90.
8. Sieunarine K, Manmohansingh E. Gastric duplication cyst presenting as an acute abdomen in a child. *J Pediatr Surg*. 1989;24(11):1152. doi:10.1016/s0022-3468(89)80101-0.
9. Stephen TC, Bendon RW, Nagaraj HS, Sachdeva R. Antral duplication cyst: A cause of hypergastrinemia, recurrent peptic ulceration, and hemorrhage. *J Pediatr Gastroenterol Nutr*. 1998;26(2):216–24.
10. Koklu E, Akcakus M, Okur H, Basbug M, Patisroglu T, Yikilmaz A. Gastroenteric duplication cysts in a newborn: Unusual clinical and radiologic presentations. *Pediatr Dev Pathol*. 2008;11:66–73.
11. Spataru RI, Popoiu MC, Ivanov M. Foregut duplicationcyst associated with esophageal atresia- one-stage neonatal surgical repair. *Indian J Surg*. 2015;77(1):52–7. doi:10.1007/s12262-014-1122-6.

Author biography

Aditya Pratap Singh, Consultant

Dinesh Kumar Barolia, Assistant Professor  <https://orcid.org/0000-0003-0617-8435>

Harsha Vinod Bathia, Consultant

Vipal H Parmar, MD Pathology

Bhavana Asit Mehta, Head of Histoanatomic Pathology

Shraddha Mehta, Consultant

Cite this article: Singh AP, Barolia DK, Bathia HV, Parmar VH, Mehta BA, Mehta S. Association of gastric duplication cyst with isolated oesophageal atresia and one additional floating rib — A rare presentation. *IP J Surg Allied Sci* 2022;4(4):145-148.