



## Case Report

# Prosthetic rehabilitation of a patient with COVID-associated mucormycosis

Hemraj Wani<sup>1,\*</sup>, Jyoti Tembhurne<sup>1</sup>, Arti Gangurde<sup>1</sup>, Niraja Jaiswal<sup>1</sup>,  
Ruturaj Khankari<sup>1</sup>

<sup>1</sup>Dept. of Prosthodontics, Govt. Dental College & Hospital, Mumbai, Maharashtra, India



### ARTICLE INFO

#### Article history:

Received 28-06-2023

Accepted 18-07-2023

Available online 13-10-2023

#### Keywords:

Fungal infection

COVID19

SARSCoV2

Prosthodontics

Obturator

### ABSTRACT

Mucormycosis is a deep invasive mycotic infection caused by a group of molds referred to as mucormycetes. The incidence of mucormycosis increased markedly in the wake of the COVID-19 pandemic. The disease can be fatal in a very high percentage of individuals and in others, its effects can drastically affect the quality of life. The prognosis depends on the early diagnosis and treatment in which dental professionals play a major role, particularly in cases of rhinomaxillary mucormycosis. The present report describes the prosthetic management of a case of rhinomaxillary mucormycosis for functional restoration.

This is an Open Access (OA) journal, and articles are distributed under the terms of the [Creative Commons Attribution-NonCommercial-ShareAlike 4.0 License](https://creativecommons.org/licenses/by-nc-sa/4.0/), which allows others to remix, tweak, and build upon the work non-commercially, as long as appropriate credit is given and the new creations are licensed under the identical terms.

For reprints contact: [reprint@ipinnovative.com](mailto:reprint@ipinnovative.com)

## 1. Introduction

Mucormycosis is a deep invasive mycotic infection caused by a group of molds referred to as mucormycetes, the most common being *Rhizopus* species.<sup>1</sup> While the infection was already more prevalent in India as compared to the Western countries, its incidence increased markedly in the wake of the COVID-19 pandemic. The disease served to 'add fuel to the fire' for patients suffering from already infected by the SARS-CoV-2 virus.

Individuals with immunocompromised states have a tendency to develop Mucormycosis as the fungus enters their body from the infected hospital equipment such as nasopharyngeal tubings in the hospitals.<sup>2</sup> Consequently, most of the infections begin in the nasomaxillary region in which the earliest signs of the infection can be detected. The predisposing factors for the development of the dreadful fungal infection include diabetes mellitus with or without keto-acidosis, hematological or other malignancies, transplantation, iron overload, corticosteroid use, trauma,

prolonged neutropenia, and malnutrition.<sup>3</sup>

The treatment includes control of metabolic diseases, antifungal medications, and surgical resection of affected tissues.<sup>4</sup> Surgery majorly involves the radical removal of the infected areas followed by prosthetic replacement. The disease can rapidly spread in the midfacial and orbital regions causing lasting damage such as palatal defects, maxillectomy, oro-antral fistula, blindness, and associated craniofacial damage.<sup>5</sup> Therefore, the prognosis depends on the early diagnosis and treatment in which dental professionals play a major role, particularly in cases of rhinomaxillary mucormycosis.<sup>6</sup>

The present report describes the prosthetic management of a case of rhinomaxillary mucormycosis for functional restoration.

## 2. Case Report

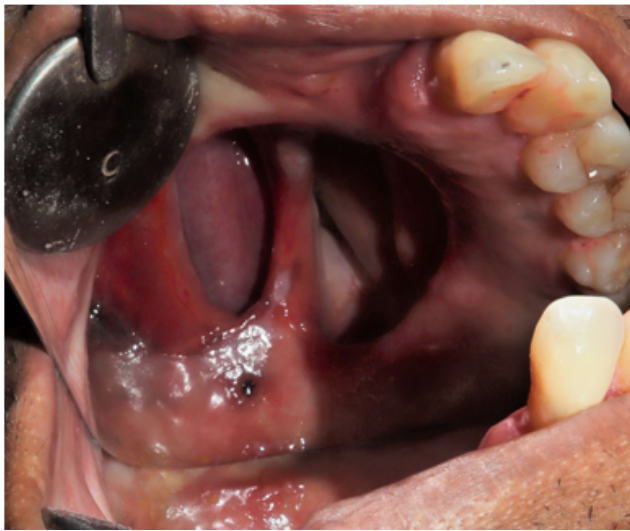A 46-year-old male patient complained of nasal regurgitation of water and food, nasal twang in voice, and loss of facial appearance. A medical history of maxillectomy due to COVID-19-associated mucormycosis

\* Corresponding author.

E-mail address: [hemrajwani6894@gmail.com](mailto:hemrajwani6894@gmail.com) (H. Wani).

ten months back was elicited along with a history of diabetes mellitus for the past five years. after contracting COVID-19 infection. Medical history revealed that the patient is diabetic for five years and underwent maxillectomy for COVID-associated mucormycosis of the maxilla 10 months back. The treatment plan was to fabricate a hollow bulb obturator.

Extraoral examination revealed asymmetry of the face with collapsed cheek and prominent nasolabial fold on the right side of the face. Intraoral examination revealed complete healing of the residual maxillary defect. Oro-antral communication could be seen due to partial maxillectomy on the right side. The defect present was of Aramany's Class-IV type. All the teeth in the maxillary right quadrant and the left central incisor were missing.



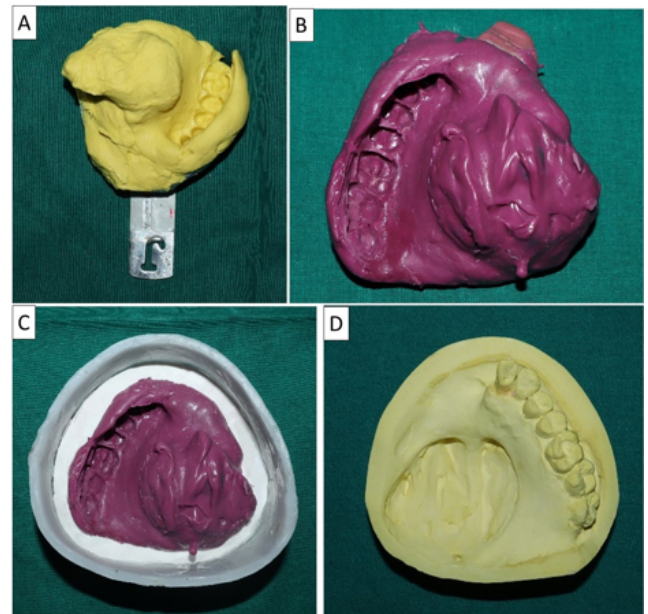
**Fig. 1:** Oro-antral defect 10 months after surgical treatment of COVID-associated mucormycosis

missing on the right side and a radiolucency extending into the maxillary sinus were observed. After detailed elicitation of history and intraoral, extraoral, and radiographic examination, a treatment plan was tailored.

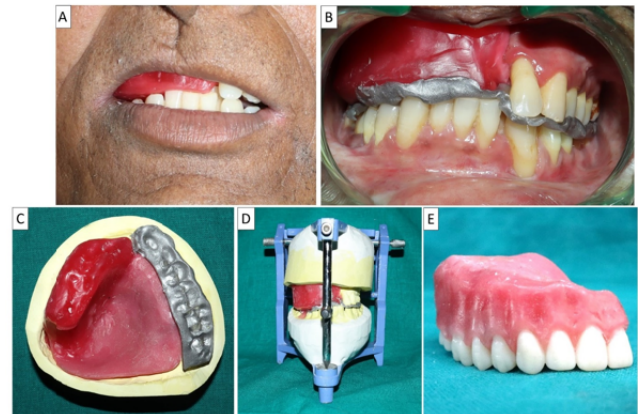
After oral prophylaxis, a primary impression was made with irreversible hydrocolloid impression material using a stock tray (Figure 2 A). The primary impression was poured with dental plaster and after retrieval of the primary cast, a special tray was fabricated with self-cure acrylic resin.

Border molding was performed with low fusing green stick impression compound and the full extent of the defect was recorded using an impression compound. The impression compound was scrapped roughly 1 mm for making space for secondary impression material. A regular body polyvinyl siloxane impression paste was used to make the final impression. (Figure 2 B).

The reverse beading of the final impression was done using a plaster-pumice mixture. A land area of 2 mm was



**Fig. 2:** A) Primary impression, B) Final impression, C) Beading and boxing of final impression, and D) Master cast

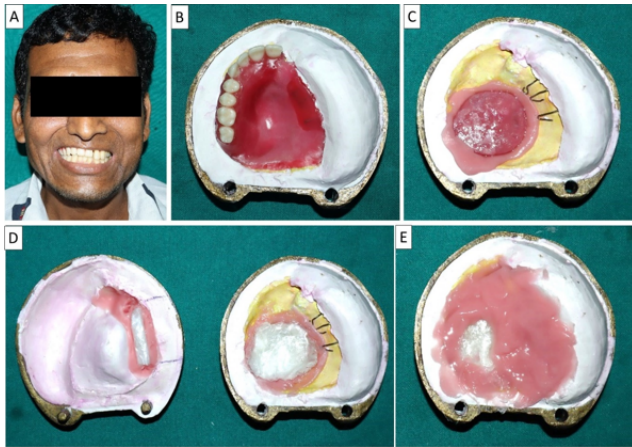


**Fig. 3:** A) Jaw relation; B) Bite registration; C) Base plater with registered jaw relation and recorded bite; D) Casts mounted on mean value articulator; E) Teeth arrangement in trial denture

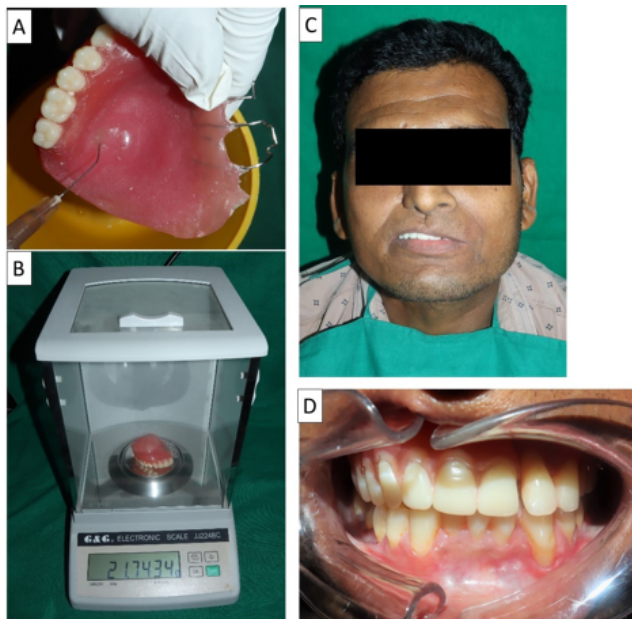created following which boxing of the impression was done using boxing wax (Figure 2 C). The final impression was then poured with type III gypsum to obtain the final cast (Figure 2 D). The wax occlusal rims were fabricated over an acrylic record base using baseplate wax. Occlusal jaw relation records were obtained (Figure 3 A) followed by bite registration with Alu wax (Figure 3 B and C). The maxillary and mandibular casts were then mounted on a mean value articulator (Figure 3 D) followed by the arrangement of acrylic teeth in the trial denture (Figure 3 E).

Denture try-in was done to evaluate the occlusion, aesthetics, and phonetics (Figure 4 A). A C-clasp on the maxillary left first premolar and Adam's clasp on the first





**Fig. 4:** A) Denture try-in; B) Flasking of denture; C) Dewaxing; D) Placement of plastic bag filled with sand; E) Packing and processing.



**Fig. 5:** A) Removal of salt from the prosthesis by injection and water; B) Weight of the prosthesis; and Patient with denture C) Extraoral view and D) Intraoral view

molar were provided for retention of the denture. The final wax-up was done followed by flasking (Figure 4 B) and dewaxing (Figure 4 C). As for the sealing of the antral defect, a hollow-bulb obturator was planned. To make the obturator hollow, a plastic bag filled with salt in the defect area was used during packing (Figure 4 D). The salt was removed from the prosthesis by making a small hole in the plastic bag through the acrylic and injecting water (Figure 5 A). The weight of the final prosthesis was 21g (Figure 5 B). A one-month follow-up revealed that the patient was satisfied with the functional results produced by

the prosthesis (Figure 5 C and D).

### 3. Discussion

Diabetic patients are particularly vulnerable to mucormycosis owing to reduced immunity, ketoacidosis, and arteritis.<sup>7</sup> India is the diabetes capital on the global scale and therefore, it already had a higher prevalence of mucormycosis.<sup>3</sup> The initiation of steroid therapy in COVID-19-infected patients coupled with the cytokine storm caused by the disease, further accentuated the prevalence of mucormycosis.<sup>6</sup> Likewise, in the present case, the patient contracted Mucormycosis infection after getting treated for COVID-19 and was treated for the same.

The patient underwent hemimaxillectomy and consequently, the entire right side of the maxilla had a defect that could be classified under grade 4 according to Aramany's classification. Aramany presented a classification system that divided maxillofacial defects into 6 categories, based on the relationship of the defect with the abutment teeth.<sup>8</sup> The class 4 defect crosses the midline and involves both sides of the maxilla, with abutment teeth present on one side which was also noted in the present case. The classification has been widely preferred by prosthodontists ever since its inception owing to its simplicity and reliability.

Retention is compromised in such defects due to the lack of a bony base and a posterior palatal seal.<sup>9</sup> To obtain adequate retention in such cases, it is crucial to adequately record the defect and obtain support from the abutment teeth by using clasps. In the present case, Adam's clasp and circumferential clasp were used on the molar and premolar teeth to obtain retentive support for the prosthesis. Missing teeth were replaced by acrylic teeth in order to achieve function.

Obturator is the most preferred choice of prosthesis in patients with post-surgical defects.<sup>10</sup> Based on the extension of the obturator into the defect, it can be classified as solid, open hollow, and closed hollow.<sup>11</sup> Hollowing is performed to reduce the weight of the obturator for better patient acceptance.

The prognosis of an obturator depends on the volume of the defect. The weight of the obturator should be as light as possible. A hollow bulb design was selected to reduce the bulk of the obturator.<sup>11,12</sup> It also adds resonance to speech which greatly improves quality. The patient was kept on frequent follow-ups to assure the stability of the obturator and ensure the patient's satisfaction in bringing back the physiologic functions.

In this manner, a prosthesis that offered adequate restoration of the function with added advantages of improved aesthetics, retention, biocompatibility, and reduce weight was fabricated for the patient. A well-tailored treatment plan with satisfactory prosthetic rehabilitation can drastically improve the quality of life for the patient.

#### 4. Conclusion

Dentists should be alert and suspicious in cases of perforation of the palate, especially in immunocompromised patients. It will be of great benefit to the patient in terms of preventing widespread surgical resection, post-surgical complications. Definitive prosthodontic treatment attempts to alleviate any anatomical and functional deficiencies. A properly formed prosthesis serves the purpose of rehabilitation of the patient's lost function and aesthetics while satisfactorily improving their quality of life. The technique described in this report can be employed in any similar case and would thus, serve to guide the clinicians in management of cases with large maxillary defects.

#### 5. Source of Funding

None.

#### 6. Conflict of Interest

None.

#### References

- Gomes MZ, Lewis RE, Kontoyiannis DP. Mucormycosis caused by unusual mucormycetes, non-Rhizopus, -Mucor, and-Lichtheimia species. *Clinical Microbiology Reviews*. 2011;24(2):411–456.
- Sirohiya P, Vig S, Mathur T, Meena JK, Panda S, Goswami G, et al. Airway management, procedural data, and in-hospital mortality records of patients undergoing surgery for mucormycosis associated with coronavirus disease (COVID-19). *J Med Mycol*. 2022;32(4):101307. doi:10.1016/j.mycmed.2022.101307.
- Sachdev SS, Chettiankandy TJ, Sardar MA, Ramaswamy E, Shah AM, Yaduwanshi K, et al. A comprehensive review of pathogenesis of mucormycosis with implications of COVID-19: Indian perspective. *J Glob Oral Health*. 2021;4:116–22.
- Brunet K, Rammaert B. Mucormycosis treatment: Recommendations, latest advances, and perspectives. *J Mycol Med*. 2020;30(3):101007. doi:10.1016/j.mycmed.2020.101007.
- Hasheminasab M, Karizmeh MS, Sharifi R, Beshkar M, Matloubi N, Asadi AA. COVID-19-associated mucormycosis involving the maxilla. *Clin Case Rep*. 2022;10(8):6165. doi:10.1002/ccr3.6165.
- Sachdev SS, Avhad SK, Chettiankandy TJ, Gaikwad RP, Jadhav P. Utility of QR codes in dental practice and academics: The era of digital revolution. *J Indian Dent Assoc*. 2022;16(5):14–8.
- Rammaert B, Lanternier F, Poirée S, Kania R, Lortholary O. Diabetes and mucormycosis: a complex interplay. *Diab Metab*. 2012;38(3):193–204.
- Gupta AD, Verma A, Islam JI, Agarwal S. Maxillofacial defects and their classification: a review. *IJAR*. 2016;4(6):109–23.
- Lin FH, Wang TC. Prosthodontic rehabilitation for edentulous patients with palatal defect: report of two cases. *J Formosan Med Assoc*. 2011;18(2):120–4.
- Corsalini M, Barile G, Catapano S, Ciocia A, Casorelli A, Siciliani R. Obturator prosthesis rehabilitation after maxillectomy: functional and aesthetical analysis in 25 patients. *Int J Environ Res Pub Health*. 2021;18(23):12524.
- Sridevi JR, Kalavathy N, Jayanthi N, Manjula N. Techniques for fabricating hollow obturator: two case reports. *SRM J Res Dent Sci*. 2014;14(3):383–9.
- Worley JL, Kniejski ME. A method for controlling the thickness of hollow obturator prostheses. *J Prosthetic Dent*. 1983;50(2):227–36.

#### Author biography

**Hemraj Wani**, Assistant Professor  <https://orcid.org/0009-0000-3401-6156>

**Jyoti Tembhurne**, Professor and HOD

**Arti Gangurde**, Associate Professor

**Niraja Jaiswal**, Associate Professor

**Ruturaj Khankari**, Post- Graduate Student

**Cite this article:** Wani H, Tembhurne J, Gangurde A, Jaiswal N, Khankari R. Prosthetic rehabilitation of a patient with COVID-associated mucormycosis. *IP J Surg Allied Sci* 2023;5(3):98-101.