

Content available at: <https://www.ipinnovative.com/open-access-journals>

IP Journal of Surgery and Allied Sciences

Journal homepage: <https://www.jsas.co.in/>

Case Report

A rare case report on subcutaneous dirofilariasis in Kerala, South India

Arunkumar Nelliparambil Revi^{1*}, Sreekumar Nelliparambil Revi²,
Usha Mary Abraham³

¹Dept. of Surgery, District Co-Operative Hospital, Thrissur, Kerala, India

²Dept. of ENT, Government Thaluk Hospital, Kunnankulam, Kerala, India

³Dept. of Pathology, Amala Institute of Medical Sciences, Thrissur, Kerala, India



ARTICLE INFO

Article history:

Received 20-09-2023

Accepted 11-10-2023

Available online 09-02-2024

Keywords:

Dirofilaria repens

Subcutaneous nodules

Dirofilariasis

Parasitic infection

ABSTRACT

The genus *Dirofilaria* includes vector-borne filarial nematodes, which usually infect carnivore hosts. This report aims to investigate various clinical manifestations of Human Dirofilariasis. A 44-year-old lady presented with a complaint of left neck pain of 2 weeks duration. On examination, a 2 x 2 cm swelling with tenderness was noted in the upper 1/3rd of the left sternocleidomastoid muscle. The patient was subjected to further investigations. The ultrasonography revealed a nodular lesion measuring 10.4 x 6.7 x 6.9 mm in the upper part of the left sternocleidomastoid muscle with alive moving dirofilarial worms. An excision Biopsy was performed and an HPE confirmed the diagnosis of intramuscular Dirofilariasis. In order to decrease the incidence of this disease through accurate diagnosis, and patient care, it is crucial to track the cases of human Dirofilariasis and increase awareness of these infections, diagnostic procedures, and vector control techniques.

This is an Open Access (OA) journal, and articles are distributed under the terms of the [Creative Commons Attribution-NonCommercial-ShareAlike 4.0 License](https://creativecommons.org/licenses/by-nc-sa/4.0/), which allows others to remix, tweak, and build upon the work non-commercially, as long as appropriate credit is given and the new creations are licensed under the identical terms.

For reprints contact: reprint@ipinnovative.com

1. Introduction

Dirofilariasis is categorised under the group of parasitic infections caused by filarial nematodes belonging to the genus *Dirofilaria* (Nematoda, Filarioidea, Onchocercidae).¹ Various species under this genus include *Dirofilaria repens*, *Dirofilaria immitis*, *Dirofilaria tenuis* and *Dirofilaria ursi*.²⁻⁴ *D. repens* primarily infects the subcutaneous tissue of dogs, foxes, and cats, while *D. immitis* inhabits the right ventricle and pulmonary artery of dogs and cats.¹

Many European nations have recorded cases of human dirofilariasis caused by *Dirofilaria repens*. Sri Lanka is the most impacted nation in Asia, with a canine infection rate of about 60%.⁵ Inflammatory subcutaneous nodules caused by the worm in exposed areas such as the face, orbits, upper limb, lower limb, chest wall, and male genitalia are the most

typical presentation of the disease.⁶

The vectors for this parasite include Adult female *Culex*, *Aedes* and *Anopheles* mosquitoes. The microfilaria are ingested by the vectors as they take the blood meal of an infected host. The third stage larva of microfilaria develops in the Malpighian tubules of mosquitoes before migrating through the body cavity to the proboscis. When an infected mosquito bites the dogs or other hosts, such as humans, during a subsequent blood meal, disease transmission occurs.^{7,8}

2. Case Report

A 44-year-old lady presented with left neck pain of 2 weeks duration. On examination, a 2 x 2 cm swelling with tenderness was noted in the upper 1/3rd of the left sternocleidomastoid muscle (Figure 1). The ultrasonography disclosed a nodular lesion measuring

* Corresponding author.

E-mail address: arunnel666@gmail.com (A. N. Revi).

10.4 x 6.7 x 6.9 mm in the upper part of the left sternocleidomastoid muscle with alive moving dirofilarial worms(Figure 2).

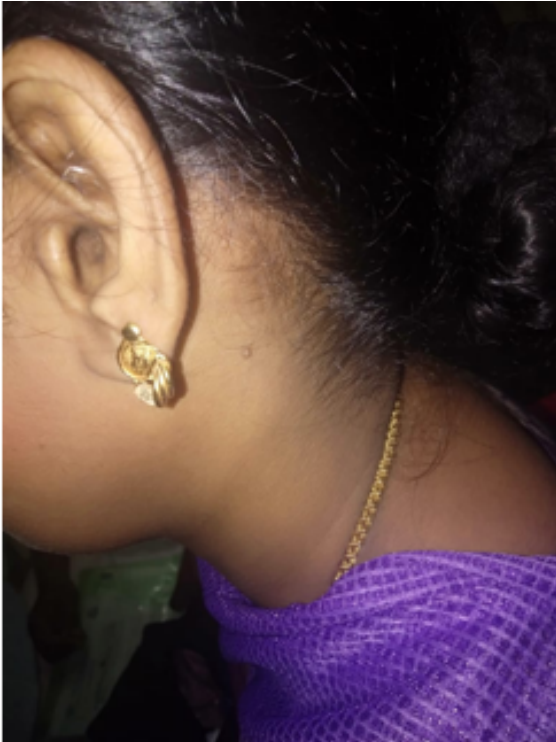

Figure 1: Showing subcutaneous nodule in the left sternocleidomastoid upper 1/3rd

Surgical excision of the swelling was performed under general anesthesia (GA). A cross sectional examination of the biopsy specimen showed a tiny cystic cavity measuring 5 mm in greatest dimension, and containing a worm measuring 0.5 cm in length (Figure 3). Microscopy revealed sections of skeletal muscle with a cystic cavity containing cross sections of a worm, morphology resembling that of *Dirofilaria repens* and surrounded by mixed inflammatory infiltrate (Figure 4 a and b), thus confirming the diagnosis of intramuscular Dirofilariasis.

The patient was started on anti-helminthics post-operatively and successfully discharged on the 3rd postoperative day.

3. Discussion

Human dirofilariasis can be divided into pulmonary dirofilariasis (*D. immitis*) and subcutaneous dirofilariasis (*D. repens*, *D. tenuis*, and others). Subcutaneous and submucosal lesions are the symptoms that are most frequently observed.³

According to the open-access literature, between 30 and 60 percent of canines in various parts of the nation are affected, and mosquitoes like *Aedes aegypti*,

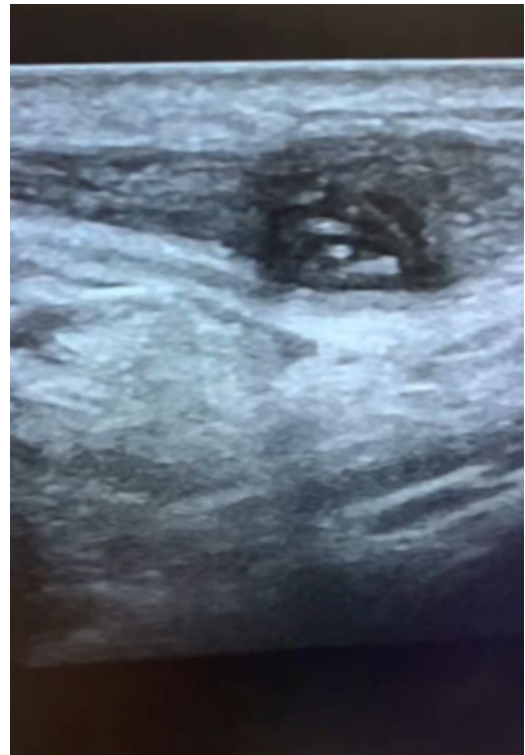


Figure 2: USG showing a nodular lesion measuring 10.4 x 6.7 x 6.9 mm in the upper part of left sternocleidomastoid muscle with moving Dirofilarial worms.

Armigeres subalbatus, *Mansonia uniformis*, and *Mansonia annulifera* are the vectors that are involved in transmitting the disease.^{3,5,8} Since humans are not the natural hosts of Dirofilarial worms but rather accidental dead-end hosts, it is found that the infectious larvae injected by mosquito bites in humans fail to attain full maturity and hence cannot express larvae in the bloodstream, which explains the rarity of human microfilaremia. Dirofilariasis cannot be spread from person to person since its natural mode of transmission involves microfilariae, which in no way infect humans.⁹ Anti-filarial/anthelmintic drugs are ineffective in the majority of the documented cases because there are no microfilariae in the blood stream.⁵ As a result, the treatment that is a combination of complete excision of the nodule and worm extraction is observed to be usually successful. In the literature, surgical excision and parasite isolation are more frequently presented as primary diagnostic and therapeutic approach at the same time. In the instance being discussed, the primary diagnostic technique was ultrasound, which is a fairly reliable way to identify subcutaneous filariasis. Although the parasitological and patho-histological analyses are necessary for the final confirmation of the diagnosis, ultrasound scan can also very confidently resolve the differential diagnosis of the subcutaneous nodule.

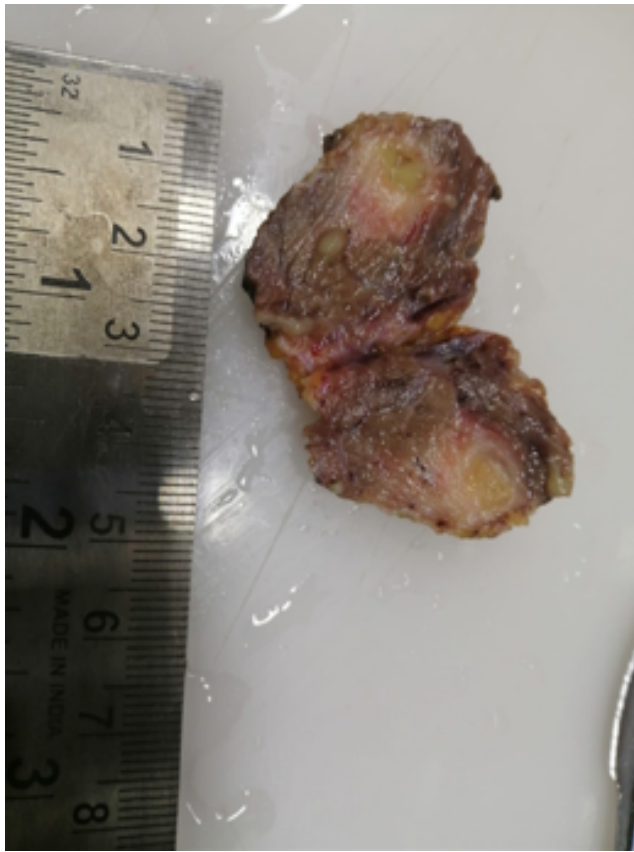


Figure 3: Showing excision biopsy specimen showing *Dirofilaria* worm measuring 0.5 cm in length

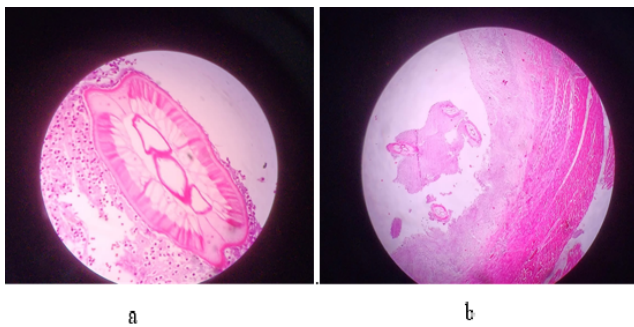


Figure 4: a; and b; showing cross section of the *Dirofilaria* worm surrounded by mixed inflammatory infiltrates

4. Conclusion

Although the number of human infections with *D. repens* has been rising in tropical regions, many of them remain undiagnosed or unreported. Due to the presence of

disease-transmission vectors, this could result in a sudden outbreak of this particular disease. In order to decrease the prevalence of this disease through controlling vector densities, accurate diagnosis and patient care, there is a need for the acquisition of greater knowledge of this infection, diagnostic procedures and vector control methods.

5. Source of Funding

None.


6. Conflict of Interest

None.

References

1. Gunathilaka N, Siriwardana S, Wijesooriya L, Gunaratne G, Perera N. Subcutaneous *Dirofilaria* Caused by *Dirofilaria* (Nochtiella) Repens in Sri Lanka: A Potential Risk of Transmitting Human *Dirofilaria*. *SAGE Open Med Case Rep*. 2017;5:2050313X17701373. doi:10.1177/2050313X17701373.
2. Achappa B, Madi D, Mahalingam S. An interesting case of a subcutaneous nodule. *J Clin Diagn Res*. 2013;7(2):364–5.
3. Nath R, Gogoi R, Bordoloi N, Gogoi TO. Ocular *Dirofilaria*. *Indian J Pathol Microb*. 2010;53(1):157.
4. Misovic M, Kostic D, Krstic B, Golubović J, Kosanovic T, Diagnostics, et al. 2018.
5. Senanayake MP, Infaq MLM, Adikaram SGS, Udagama PV. Ocular and Subcutaneous *Dirofilaria* in a Sri Lankan Infant: An Environmental Hazard Caused by Dogs and Mosquitoes. *Paediatr Int Child Health*. 2013;33(2):111–2.
6. Pampiglione S, Rivasi F. Human *Dirofilaria* Due to *Dirofilaria* (Nochtiella) Repens: An Update of World Literature from. *Parassitologia*. 1995;42(3-4):231–54.
7. Sabu L, Devada K, Subramanian H. *Dirofilaria* in Dogs and Humans in Kerala. *Indian J Med Res*. 2005;121(5):691–3.
8. Permi HS, Veena S, Prasad HK, Kumar YS, Mohan R, Shetty KJ. Subcutaneous Human *Dirofilaria* Due to *Dirofilaria* Repens: Report of Two Cases. *J Glob Infect Dis*. 2011;2011(2):199–201.
9. Reddy MV. Human *Dirofilaria*: An Emerging Zoonosis. *Trop Parasitol*. 2013;3(1):2–3.

Author biography

Arunkumar Nelliparambil Revi, Consultant General and Laparoscopic Surgeon  <https://orcid.org/0000-0002-3702-5928>

Sreekumar Nelliparambil Revi, Junior Consultant ENT

Usha Mary Abraham, Associate Professor

Cite this article: Revi AN, Revi SN, Abraham UM. A rare case report on subcutaneous dirofilariasis in Kerala, South India. *IP J Surg Allied Sci* 2023;5(4):123-125.