



Letter to Editor

Leydig cell tumor – An uncommon paediatric testicular tumor

Aditya Pratap Singh¹, Dinesh Kumar Barolia^{2*}, Harsha Vinod Bathia¹,
Vipal H Parmar³, Bhavana Asit Mehta³, Shraddha Mehta¹

¹Bhagwan Mahavir Hospital, Sumerpur, Pali, Rajasthan, India

²Jawaharlal Nehru Medical College, Ajmer, Rajasthan, India

³Neuberg Supratech Reference Laboratories, Ahmedabad, Gujarat, India



ARTICLE INFO

Article history:

Received 14-01-2024

Accepted 31-01-2024

Available online 09-02-2024

This is an Open Access (OA) journal, and articles are distributed under the terms of the [Creative Commons Attribution-NonCommercial-ShareAlike 4.0 License](https://creativecommons.org/licenses/by-nc-sa/4.0/), which allows others to remix, tweak, and build upon the work non-commercially, as long as appropriate credit is given and the new creations are licensed under the identical terms.

For reprints contact: reprint@ipinnovative.com

Dear Sir,

Leydig cell tumor is a rare testicular tumor. Of the all solid tumors of childhood, testicular tumor comprises only 1% of these tumors. Out of 1%, the leydig cell tumor is a rare testicular tumor not only in paediatric age group but also in the adult population.¹⁻³

A 13 year's old male child presented with right scrotal swelling since one year. The swelling was gradually increasing in size. On inspection large right testicular impression was visible compare to left testis. On palpation right testis was oval, smooth surface, non-tender but larger than left testis. He has features of precocious puberty like sparse beard, moustache, and pubertal hair. Trunk was appearing large. Both lower limbs were small comparatively. Complete blood counts were within normal limits. Serum testosterone, alkaline phosphatase, and calcium were raised. Serum FSH, LH, beta HCG, and estradiol levels were normal in range. X-ray chest was normal. Ultra sound showed a space occupying lesion with mixed echogenicity in right testis. Contrast enhanced CT scan of chest and abdomen was normal, no mitotic activity was seen. After anaesthetic fitness, we explore the right testis through high inguinal approach and orchidectomy done. Histopathology of excised specimen confirms the

diagnosis of leydig cell tumor. Presence of polygonal cells with eosinophilic cytoplasm and containing multiple nucleoli made the diagnosis firm (Figure 1 A & B).

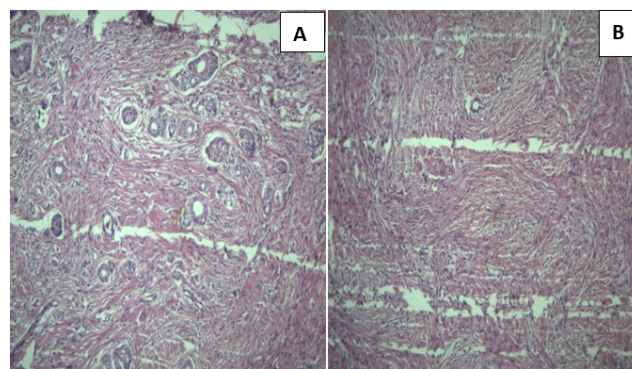


Figure 1: A: & B: [H &E] – showing polygonal cells with eosinophilic cytoplasm and containing multiple nucleoli

Testicular teratoma and yolk sac tumor are common tumor of childhood testis.^{3,4} Very few cases of leydig cell tumor reported in English literature with features of precocious puberty in childhood group. We are just adding this one more case.

* Corresponding author.

E-mail address: dbaroliarmt@gmail.com (D. K. Barolia).

Conflict of Interest


None.

References

1. Cecchetto G, Alaggio R, Bisogno G, Virgone C, Ferrari V, Terenziani M. Sex cord-stromal tumors of the testis in children. A clinicopathologic report from the Italian TREP project. *J Pediatr Surg.* 2010;45(9):1868–73.
2. Pohl HG, Shukla AR, Metcalf PD, Cilento BG, Retik AB, Bagli DJ. Prepubertal testis tumors: Actual prevalence rate of histological types. *J Urol.* 2004;170:2370–2.
3. Maizlin II, Dellinger M, Gow KW, Goldin AB, Goldfarb M, Nuchtern JG. Testicular tumors in prepubescent patients. *J Pediatr Surg.* 2017;53(9):29102152.
4. Rescorla FJ, Ross JH, Billmire DF. Surveillance after initial surgery for stage I pediatric and adolescent boys with malignant testicular germ cell tumors: report from the Children’s Oncology Group. *J Pediatr Surg.* 2015;50:1000–3.

Author biography

Aditya Pratap Singh, Consultant

Dinesh Kumar Barolia, Assistant Professor  <https://orcid.org/0000-0003-0617-8435>

Harsha Vinod Bathia, Consultant

Vipal H Parmar, Consultant

Bhavana Asit Mehta, Consultant

Shraddha Mehta, Consultant

Cite this article: Singh AP, Barolia DK, Bathia HV, Parmar VH, Mehta BA, Mehta S. Leydig cell tumor – An uncommon paediatric testicular tumor. *IP J Surg Allied Sci* 2023;5(4):136-137.