



Case Report

Role of amniotic membrane allograft in pediatric facial scald burn

Anirudh Dwajan¹, Ravi Kumar Chittoria^{2*}, Amrutha J S³

¹Dept. of Surgery, Jawaharlal Institute of Postgraduate Medical Education and Research, Puducherry, India

²Dept. of Plastic Surgery and Telemedicine, Jawaharlal Institute of Postgraduate Medical Education and Research, Puducherry, India

³Dept. of Plastic Surgery, Jawaharlal Institute of Postgraduate Medical Education and Research, Puducherry, India



ARTICLE INFO

Article history:

Received 18-01-2024

Accepted 05-02-2024

Available online xx xx xxxx

Keywords:

Amniotic membrane

Regenerative

Pediatric

Second degree scald burns

ABSTRACT

Burns are one of the most common injuries among the children, which could due to thermal, scald, electrical burn injuries. Scald injuries tend to be the most common type of burn injury under the age of five, accounting for over 65% of the cases. In current scenario, various scaffolds are used to improve the quality of healing process and reduce the scar formation. Collagen acts as a scaffold through which regeneration of tissues occurs and also helps in new vessel formation. Other scaffolds like amniotic membrane helps in proper epithelization and reduces scarring. It also has unique anti inflammatory, bacteriostatic property. In this study we used amniotic membrane heterograft as a biological dressing in a paediatric patient with burn wounds to face.

This is an Open Access (OA) journal, and articles are distributed under the terms of the [Creative Commons Attribution-NonCommercial-ShareAlike 4.0 License](https://creativecommons.org/licenses/by-nc-sa/4.0/), which allows others to remix, tweak, and build upon the work non-commercially, as long as appropriate credit is given and the new creations are licensed under the identical terms.

For reprints contact: reprint@ipinnovative.com

1. Introduction

Wound healing is a physiological response of a living being to physical, chemical, mechanical or thermal injury. The wound healing process consists of several phases: homeostasis, inflammation, proliferation/granulation, and remodeling/maturation. Still, when the healing course deviates from the normal path, the healing does not advance past the inflammatory phase. In case of burns, there will be deficiency in normal healing. In modern medicine, usage of scaffolds either natural or synthetic has become popular and been recognized.

An ideal scaffold should consist of these key features: fitting physical, mechanical properties, physiological background to enable cell adhesion, proliferation and differentiation, a high porosity, a large surface area to volume ratio and to be flexible enough to accommodate the shape of the wound and preferably biocompatible and

biodegradable.

Collagen, synthetic or natural acts as a substitute for the dermal matrix through which epithelialization occur.¹ In the process of wound healing, degradation of collagen aids in the formation of new vessels, thereby it also helps in angiogenesis.

Amniotic membrane which is a natural scaffold has its own properties which includes its anti inflammatory, bacteriostatic, anti fibrotic, anti scarring and promotion of epithelization as well.² Since it has low immunogenicity and has its own progenitor cells, it can be an ideal choice in terms of usage of scaffolds for healing of wounds.

Silicon act as a barrier by reducing mechanical friction and transepidermal water loss which have been shown to be associated with the severity of a subsequent infection.³ In vitro study shows silicone may regulate the inflammatory growth factors that cause fibrosis and promote acute wound healing. Important elements in this process include inflammatory markers such as TNF- α , TGF- β , IL-1, and IL-

* Corresponding author.

E-mail address: drchittoria@yahoo.com (R. K. Chittoria).

6 that are also implicated in acute inflammation.

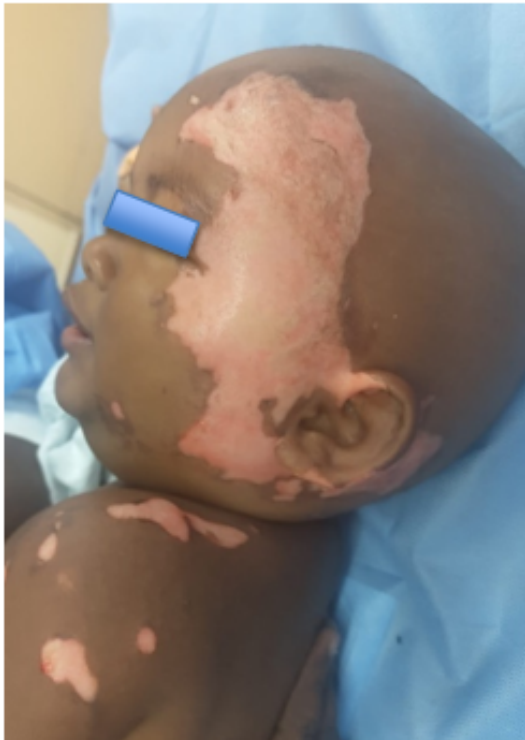

Figure 1: Second degree superficial and deep scald burns at the time of admission

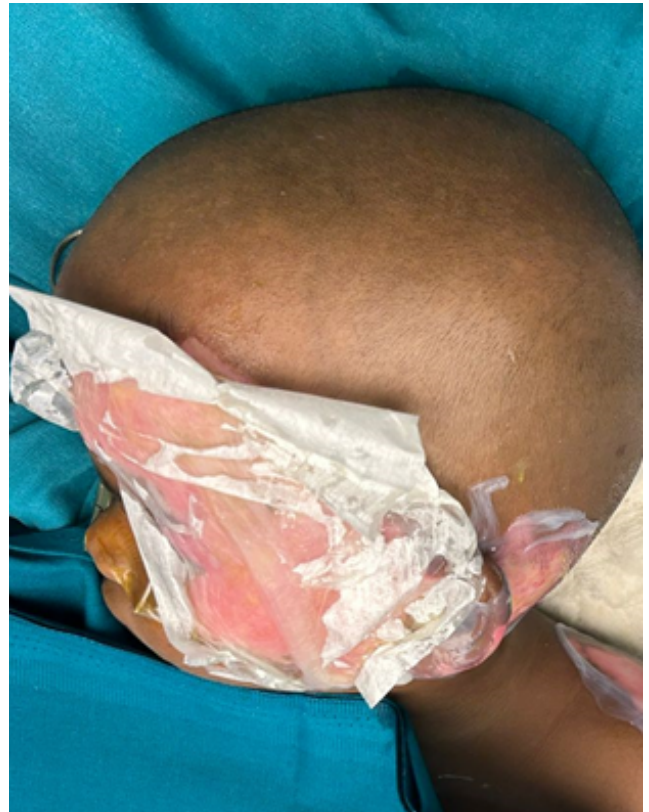


Figure 3: Three layered scaffold dressing with amnion, collagen and silicone sheet

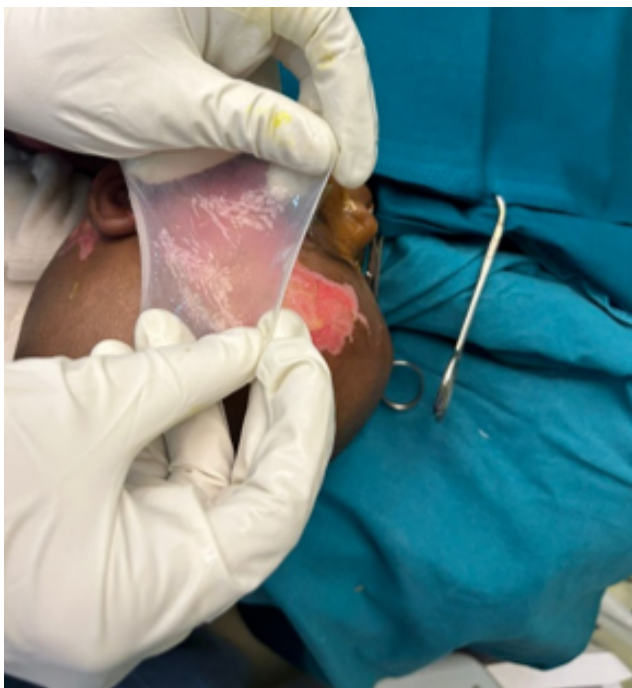


Figure 2: Amniotic membrane application

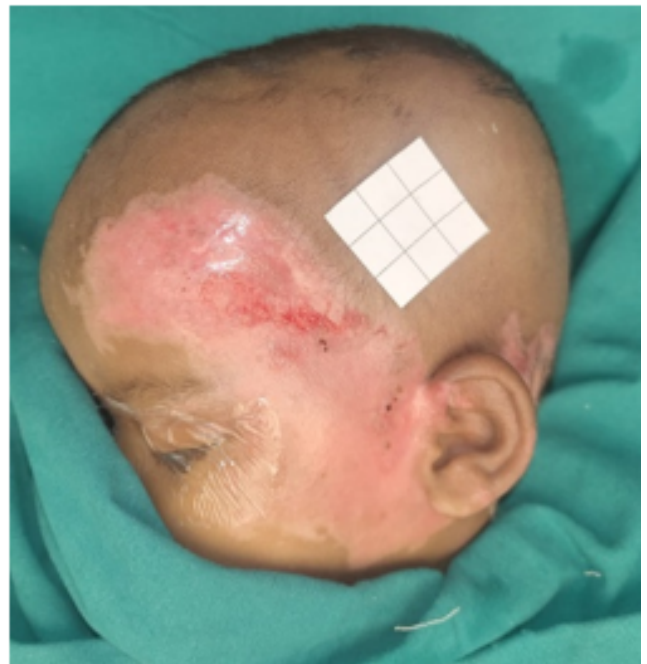

Figure 4: Healed wound

2. Materials and Methods

This study was conducted in Tertiary Care Centre in Department of Plastic Surgery after getting the department ethical committee approval. Informed consent was obtained. The subject was a 1yr - old female child who had accidental second degree scald burn injury which involves her left side of face, pinna and retroauricular region, left arm and forearm. She was taken to nearby hospital within 30min-inadequate initial resuscitation. Child developed blistering and swelling around left eye next day and presented to our center after a delay of 12hrs. (Figure-1) She was admitted in tertiary burn care unit and initial resuscitation with intravenous fluids, analgesics and prophylactic antibiotics started. On postburn day 2, the three layered scaffold dressing was made and applied over deeper burn areas after dermabrasion assisted tangential excision. The three layers of scaffold was made by sterile amniotic membrane, dry collagen sheet and silicone sheet. The layer of amniotic membrane was in direct contact with the wound. (figure-2,3) Amniotic membrane was harvested from freshly delivered placenta. It is thoroughly washed and stored in antibiotic solution in refrigerator. The dressing was kept intact for 7 days. On the 7th postoperative day, the amniotic membrane was completely resorbed and the silicon sheet layer was also removed.

3. Results

Intraoperative and post-operative periods were uneventful for the patient. On post operative day 7, dressing was opened and it showed significant areas of re-epithelialization and healing. All second degree superficial burn wound healed completely (Figure-4). No complications and side effects were noted during entire procedure.

4. Discussion

Partial-thickness burn wounds can heal spontaneously, whereas full-thickness burn wounds require skin grafting for definitive wound closure. Historically, the gold standard for closure of excised full-thickness burn wounds is split-thickness skin autograft. Patients with very large burn wounds have limited donor sites for harvesting of autograft and may benefit from the use of skin substitutes. Engineered skin substitutes that may provide temporary wound coverage until donor sites are ready to be reharvested for autograft, or if they contain autologous cells, may provide permanent wound closure. Relatively few permanent skin substitutes are currently available, but developments in tissue engineering of human skin are expected to soon provide improved models for increased availability and enhanced healing of burn wounds.⁴ Commercially available Dermal Regeneration Template is a two-layered skin regeneration system.⁵ The outer layer of this system is made of thin silicone film act as the epidermis of skin.

This layer helps in protecting wound from infection and controls in loss of both heat and moisture. The outer collagen glycosaminoglycan (GAG) thermal layer functions as a biodegradable template that helps in regeneration of dermal tissue neodermis by the body. The inner layer of dermal regeneration template is made of complex matrix of cross-linked fibers. The porous material of the template helps in regeneration of skin. The cross-linked fiber material of dermal regeneration template acts a scaffold for the regrowth of skin layer. Once the dermal skin layer is regenerated, the outer layer of template is removed and is replaced with a thin epidermal skin graft. This procedure leaves the wound to a flexible, growing and allows permanent regeneration of skin. It allows faster healing of wound with minimum scarring. Here we have tried to replicate the same mechanism in our indigenously made dermal regeneration scaffold. The indigenous dermal regeneration scaffold prepared from silicone sheet, dry collagen sheets and amnion is cost-effective and can be easily prepared and used on wounds. Thus, it can be used in hospital settings in developing countries where the affordability of commercial regeneration template is doubtful.

5. Conclusion

The adoption of this cost effective amniotic membrane based regenerative scaffold dressing in second degree scald burns has been proven effective in this study. It hastens the overall healing time of second degree superficial and deep wound to within a week. Thus minimizing the total hospital stay and infection rates. However a large multicentric, double-blinded control research with statistical analysis is needed.

6. Source of Funding

None.

7. Conflict of Interest

None.

References

1. Lazovic G, Colic M, Grubor M, Jovanovic M. The application of collagen sheet in open wound healing. *Ann Burns Fire Disast.* 2005;18:151–7.
2. Bose B. Burn wound dressing with human amniotic membrane. *Ann R Coll Surg Engl.* 1979;61(6):444–51.
3. Lucattelli E, Cipriani F, Pascone C, Lonardo D. Non-Healing Burn Wound Treatment With A Sterile Silicone Gel. *Ann Burns Fire Disasters.* 1931;34(1):53–7.
4. Frame JD, Still J, Lecoadou AL, Carstens MH, Lorenz C, Orlet H, et al. Use of dermal regeneration template in contracture release procedures: a multicenter evaluation. *Plast Reconstr Surg.* 2004;113:1330–8.
5. Moiemens NS, Staiano JJ, Ojeh NO, Thway Y, Frame JD. Reconstructive surgery with a dermal regeneration template: clinical and histologic study. *Plast Reconstr.* 2001;108:93–103.

Author biography

Anirudh Dwajan, Junior Resident

Ravi Kumar Chittoria, Professor and Associate Dean (Academic)

Amrutha J S, Senior Resident

Cite this article: Dwajan A, Chittoria RK, Amrutha J S. Role of amniotic membrane allograft in pediatric facial scald burn. *IP J Surg Allied Sci* 2024;6(1):37-40.