

Surgical management of renal cell carcinoma in horse shoe kidney: A case report

Gyanendra S.Mittal^{1*}, Deepak Sundriyal², Sharan Choudhri³

^{1,3}Surgical Oncologist, ²Medical Oncologist, ¹Santosh Deemed to be University, Ghaziabad, Uttar Pradesh, ²All India Institute of Medical Sciences, Rishikesh, Uttarakhand, ³Max Saket City Hospital, New Delhi, India

*Corresponding Author: Gyanendra S.Mittal

Email: g20mittal@gmail.com

Abstract

Horse shoe kidney occurs in 0.25% of general population and is more common in men with a 2:1 male to female ratio. Incidence of carcinoma in those with horse shoe kidney is about 3-4 times higher than the general population. Survival is mainly related to the histological grade and stage of the tumor. We present this case as our patient presented with features of anemia due to microscopic haematuria and vague abdominal pain. CECT abdomen and CT angiography diagnosed as heterogeneous mass lesion in the left moiety of horse shoe kidney with an independent vascular supply to the isthmus. Case was successfully operated by nephron sparing surgery with uneventful recovery.

Keywords: Papillary carcinoma, Horse shoe kidney, Nephron sparing surgery.

Introduction

Horse shoe kidney (HSK) was discovered first time in 1521 by Jacopo Berengario da Carpi. It occurs in 0.25% of general population and is perhaps the most frequent anomaly of kidney fusion. In this, two kidneys are joined by isthmus (a parenchymatous or fibrous tissue bridge) at their lower poles. With a male to female ratio of 2:1, it is more frequent in men.^{1,2} This phenomenon happens between the 4th and 6th weeks of gestation in the embryo, when ureteral yolk enters into the renal blastema. Renal pelvises face forward and this usually occurs before rotation of the kidney. The calyceal system is atypical in orientation with a wide variation in their blood supply, but number of calyces is usually normal.³ although etiology of HSK is not completely understood but it may be suggested that alteration in the position of common iliac or superior mesenteric or umbilical artery is responsible. This causes alteration in the rotation and ascent of kidney which at that time situated in the lower part of abdomen.

Incidence of carcinoma in HSK is higher (although exact incidence has not been described), approximately 3-4 times greater than that of general population. Survival is dependent on the histological grade and stage of the tumor.⁴ Management approach of the tumor in HSK requires pre-operative imaging to confirm neoplastic growth, its extent and its vascular anatomy. CT angiography with 3-D reconstruction of vasculature is indispensable part of pre-operative work-up, as HSK has wide variation in its vascular supply.⁵ Aim of the evaluation should be the complete resection of the tumor with negative margins without

removal of normal functioning tissue. We managed a patient of HSK with papillary carcinoma in its left moiety by performing a nephron sparing surgery with uneventful recovery.

Case Report

An elderly lady of age 57 yrs. came to the hospital with complaints of breathlessness on exertion and mild left sided abdominal pain for 1 year. On examination, she had pallor, her abdomen was normal. Her routine blood and biochemical investigations revealed anemia (Hb- 6.7 gm %) and microscopic hematuria. CECT abdomen showed a heterogeneous mass lesion with mixed Hounsfield values of 7.5 cm diameter in the upper pole of the left moiety of a HSK (Fig.1). This kidney was malascended and placed at lower level than normal. 3-D CT angiography and reconstruction of vascular anatomy revealed a separate artery supplying the isthmus (Fig.2).

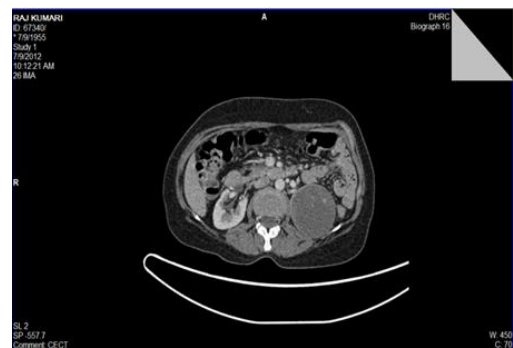


Fig. 1: Heterogeneous mass upper pole of left moiety of horse-shoe kidney

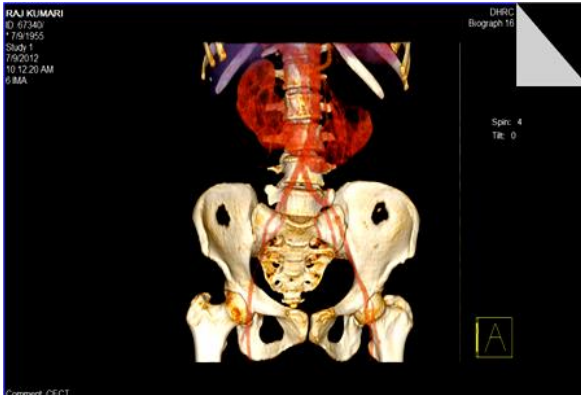


Fig. 2: Formatted view showing absence of pelvicalyceal and vascular pattern in upper pole on left side. Note the independent artery running across transverse pedicle of lumbar vertebra and supplying the isthmus

After pre-operative preparation including blood transfusion and with a diagnosis of neoplastic growth in the HSK, patient was taken for surgery. An upper midline abdominal incision was given, after mobilization of left colon a tumor of ~7x7 cm was seen at the upper pole of left moiety of the HSK.

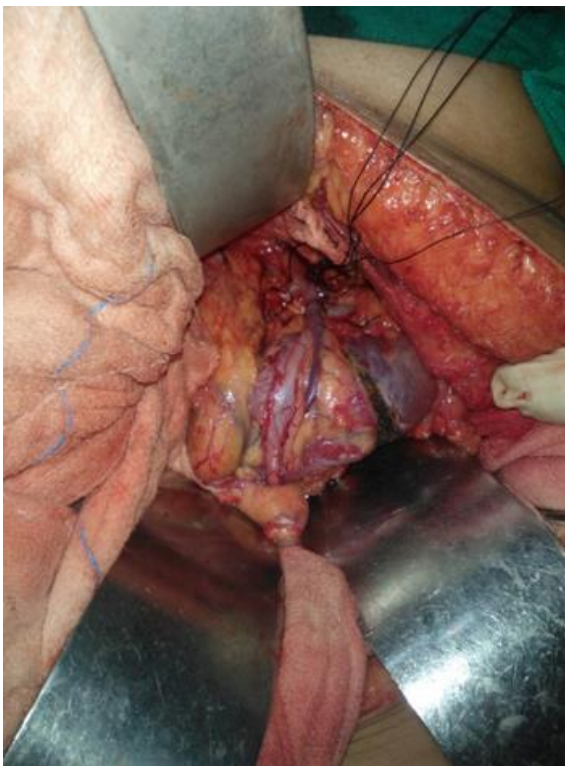


Fig. 3: Note the clear line of demarcation after division of arterial supply and sparing the isthmus

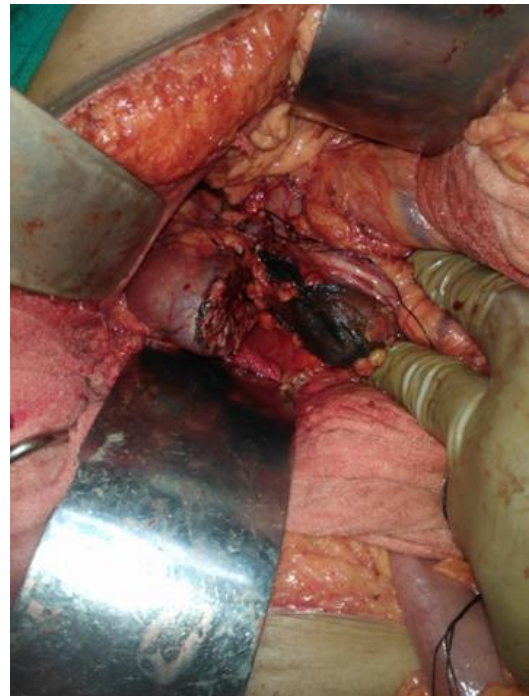


Fig. 4: Complete division of upper pole and adjacent area achieving tumor-free margin >1cm

To delineate clear vascular anatomy of hilum, meticulous dissection was performed. There was independent arterial supply to the isthmus. The left pelvis was extra renal and only the upper calyx was draining the tumor bearing area. This calyx was divided and then the vessels to the upper part of left moiety were dealt. When a distinct line of demarcation was appeared (Fig.3) above the junction of isthmus and left moiety the renal tissue along this line was divided using harmonic scalpel (Fig.4). With a free margin of ~1 cm, the tumor bearing area along with left adrenal gland, para-aortic node in the left hilar area and part of Gerota's were removed. Integrity of pelvic calyceal system on the cut surface of residual kidney and hemostasis was ensured and the procedure was completed after putting a drain. The patient was discharged on the fourth post-operative day with an uneventful recovery.

Histopathology examination showed papillary renal cell carcinoma with Fuhrman's nuclear grade-III. There was no metastasis in the removed para-aortic nodes. The resection margin, renal vein and ureter were free of the tumor.

Discussion

HSK is the most common variant among all anomalies of renal fusion. In this two renal masses lying vertically and connected to their lower poles by a isthmus (containing parenchymal or fibrous tissue

bridge) that crosses the midline. About 30% of patients remain asymptomatic in their life suggesting benign nature of the anomaly. Rest of the patients used to present with as a consequence of hydronephrosis, renal stones, pyelonephritis or less commonly neoplastic lesions.^{2,6} Most common symptom is vague abdominal flank pain that may radiate to lower abdomen or back. Carcinoma has been reported in only 123 patients⁷ with HSK with clear cell carcinoma in 47%, urothelial carcinoma in 28%, Wilms' tumor in 20% and sarcomas in 5%.⁸ Prognosis and long term survival depends upon histopathological diagnosis and stage of the tumor, it is not related to the renal anomaly.^{4,9}

Preoperative imaging as CECT is an essential in planning of surgery in a case of tumor in HSK. CT angiography with 3-D reconstruction or Magnetic resonance angiography (MRA) or venography (MRV) should always be done to delineate the vascular anatomy. As there is a great variability in the blood supply of HSK. Angiography of the specific tumor area is able to reduce the intraoperative vascular injury and also reduce the postoperative need for blood transfusions.¹⁰ Venographic imaging may be less accurate in the fused kidney due to variable venous anatomy and smaller caliber of renal veins. Nowadays separate angiographic examination of renal vascular anatomy has been eliminated due to 3-D image reconstruction on modern CT machine. In our case pre-operative CT reconstruction showed a separate arterial supply to the isthmus that was an essential part of workup and helped us a lot intra-operatively.

The surgery should be done by trans-peritoneal route through a subcostal or midline or laparoscopic approach. After mobilization of colon, early ligation of the renal artery and vein should be done before tumor manipulation. This is an essential and standard technique in the management of renal carcinoma to avoid tumor embolization. We used midline approach in our case as kidney was lower lying due to incomplete ascent. After careful dissection at the hilum to demonstrated individual branches to the pelvi-calyceal system and judicious use of vascular clamps, we were able to perform a nephron-sparing surgery along with maintaining oncological principles.

Anatomically, isthmus receives an additional arterial supply from aorta or main renal artery and lies anterior to the aorta and vena cava. To achieve complete oncological clearance, division of isthmus may be an essential part of surgery in case of carcinoma in HSK as it also normalizes the course of

the ureters. But in our case we were able to achieve adequate margins and complete tumor clearance without division of isthmus, and preserved additional renal parenchyma.

Papillary renal cell carcinoma is an uncommon entity in HSK. With modern imaging, diagnosis of this disease is not very difficult but preserving the maximum functional renal tissue may be a challenge. In our view, accurate preoperative assessment of renal vascular supply is essential. Choice of surgical incision and meticulous surgical dissection helps to follow safe oncological principles and preserving maximum functional renal tissue.

Source of funding

None.

Conflict of interest

None.

References

1. Jones L, Reeves M, Wingo S. Malignant tumor in a horseshoe kidney. *Urol J* 2007;4(1):46-8.
2. Glenn JF. Analysis of 51 patients with horseshoe kidney. *N Eng J Med* 1959;261:684-87.
3. Hohenfellner M. Tumor in the horseshoe kidney: clinical implications and review of embryogenesis. *J Urol* 1992;147(4):1098-102.
4. Vázquez S, Calahorra-Rodríguez A. Patología tumoral en el riñón en herradura. *Actas Urol Esp* 1994;18:764-7.
5. Arce Y, Trias I, Santaularia JM, Antonio Rosales. Aplicación clínica de las actuales clasificaciones del cáncer renal. *Actas Urol Esp* 2006;30:372-85.
6. Boatman DL, Cornell SH, Kölln CP. The arterial supply of horseshoe kidney. *Am J Roentgenol Radium Ther Nucl Med* 1971;113(3):447-51.
7. Blackard CE, Mellinger GT. Cancer in a horseshoe kidney. A report of two cases. *Arch Surg* 1968;97(4):616-27.
8. Otero García JM, Maldonado Alcaráz E, López Samano VA. Carcinoma de células claras en riñón en herradura. Descripción de un caso y revisión de la literatura. *Gac Med Mex* 2005;141(4):305-07.
9. Murphy DM, Zincke H. Transitional cell carcinoma in the horseshoe kidney: report of 3 cases and review of the literature. *Br J Urol* 1982;54:484-87.
10. Wilhelm L, Albrecht L, Kirsch M. Preoperative application of selective angiographic embolization in the treatment of focal nodular hyperplasia. *Surg Laparosc Endosc Percutan Tech* 2006;16:177-81.

How to cite: Mittal GS, Sundriyal D, Choudhri S. Surgical management of renal cell carcinoma in horse shoe kidney: A case report. *J Surg Allied Sci* 2020;2(1):26-8.