



## Case Report

# Successful emergency surgery in a patient on dabigatran, after reversing the anticoagulation effect using Idarucizumab – A case report

Rajesh Badani<sup>1</sup>, Annapurna Kalia<sup>1</sup>, Prakash Valse<sup>2</sup>, Amod Tilak<sup>3</sup>,  
Arun Kumar Dahiya<sup>3,\*</sup>

<sup>1</sup>Dept. of Cardiology, Aditya Birla Memorial Hospital, Pune, Maharashtra, India

<sup>2</sup>Dept. of Gastrointestinal Surgery, Aditya Birla Memorial Hospital, Pune, Maharashtra, India

<sup>3</sup>Dept. of Medical Affairs, Boehringer Ingelheim India Pvt. Ltd, Mumbai, Maharashtra, India



## ARTICLE INFO

### Article history:

Received 09-11-2020

Accepted 18-12-2020

Available online 01-02-2021

### Keywords:

Anticoagulant  
dabigatran etexilate  
emergency surgery  
idarucizumab

## ABSTRACT

Surgeons are required to keep themselves updated on ever-increasing list of drugs that may influence the outcomes of surgeries, especially in an emergency scenario. Here, we report a case of acute abdomen, wherein the patient was on dabigatran, a 'Non-vit. K/Direct Oral Anti-Coagulant' (NOAC/DOAC). NOACs are relatively recent additions to anticoagulation care. In our patient, dabigatran was prescribed by a cardiologist to prevent the occurrence of stroke in the patient who was suffering from atrial fibrillation. In case of uncontrolled bleeding, or when an emergency surgery is needed, the effect of dabigatran can be reversed with the use of a specific monoclonal antibody – idarucizumab. Knowledge about the drug & its reversal agent, and a multi-disciplinary approach, could make it possible for us to operate on the patient, and avoid excessive bleeding during the surgery.

© This is an open access article distributed under the terms of the Creative Commons Attribution License (<https://creativecommons.org/licenses/by/4.0/>) which permits unrestricted use, distribution, and reproduction in any medium, provided the original author and source are credited.

## 1. Introduction

Many patients requiring emergency surgeries & procedures are on one or the other drug that may affect the outcome of the intervention. Surgeons are required to keep themselves updated on ever-increasing list of such drugs. This is especially relevant in case of elderly patients, who are more likely to suffer from multiple diseases, and thus may be on multiple drugs.

Atrial fibrillation (AF) is one of the most commonly observed arrhythmias in the elderly. There is an increased incidence of ischemic stroke in patients of atrial fibrillation. The management of AF, thus focuses on stroke prevention along with rate and/or rhythm control. Oral anticoagulants form the mainstay for the prevention of strokes due to thromboembolism in patients of AF. The Vitamin-K antagonists oral anticoagulants (VKAs) group of drugs

have been, to a great extent, replaced by the non-VKA oral anticoagulants (NOACs) since the RE-LY (dabigatran), ROCKET AF (rivaroxaban) and ARISTOTLE (Apixaban) trials were published. NOACs are now the preferred drugs of choice for the management of non-valvular AF (NVAF) in eligible patients.<sup>1</sup>

Various clinical trials and real-world studies have demonstrated that NOACs are similar or superior to warfarin/VKAs in terms of efficacy, and superior in terms of safety.<sup>2</sup> However, patients on any anticoagulant may experience major bleeding events or may require emergency surgical interventions. The patients on warfarin in such situations are managed using a combination of reversal strategies, which includes fresh frozen plasma (FFP), cryoprecipitates and Vitamin K injections. Till 2015, management of such emergencies in patients on NOACs posed a challenge, as there was no specific reversal agent available.<sup>3</sup>

\* Corresponding author.

E-mail address: [arunkumar.dahiya@boehringer-ingelheim.com](mailto:arunkumar.dahiya@boehringer-ingelheim.com) (A. K. Dahiya).

2015 saw the approval of idarucizumab (Praxbind, Boehringer Ingelheim) by the US FDA as the specific reversal agent for dabigatran. Idarucizumab is a fully humanized monoclonal antibody Fab fragment. It is a specific antidote for dabigatran with a binding affinity 350 times higher than the affinity between dabigatran and thrombin. As a result, administration of idarucizumab results in an immediate, complete and sustained reversal of the anticoagulant effect of dabigatran. Idarucizumab was tested in the REVERSE AD trial. The dose of 5 g administered as a bolus was evaluated in patients on dabigatran (Pradaxa, Boehringer Ingelheim) presenting with major bleeding events (n=302) or requiring emergency surgical intervention (n=201).<sup>4</sup> Idarucizumab was approved in India in 2017 and has been in commercial use since.

We report a case of successful emergency surgery in a patient on dabigatran 110 mg twice daily, after reversing dabigatran's effect using specific monoclonal antibody idarucizumab.

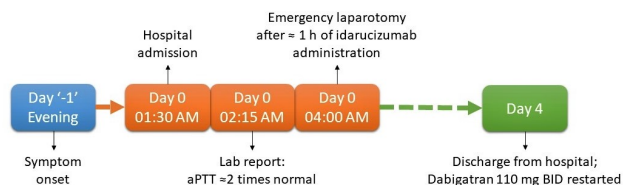
## 2. Case

A 76-year-old female patient presented to our hospital on 22<sup>nd</sup> Nov, 2019 at 1:30 am with multiple episodes of vomiting since the previous evening. There was no associated abdominal pain, fever, chest pain or breathlessness. The patient had a history of hernioplasty done in the past with ventral hernia sac and mesh repair. She was a known case with hypertension, hyperthyroidism and atrial fibrillation with a pacemaker in situ. The patient was on treatment with dabigatran (Pradaxa) 110 mg for stroke prevention.

Laboratory investigations were normal except for aPTT, which was deranged. Ultrasound examination of the abdomen demonstrated obstructed incisional hernia and small bowel obstruction. Surgery was planned. Since the last dose of Pradaxa was taken three hours prior to presentation, decision was taken to administer idarucizumab – the specific reversal agent for Pradaxa. One hour after the administration of injection idarucizumab, emergency laparotomy with mesh hernioplasty was performed under general anaesthesia. With a transverse abdominal incision, the hernia was reduced. A recurrent ventral hernia sac and a previous mesh was observed. The neck of the sack was narrow, and oedematous obstructed small bowel was visible. Various adhesions were observed in the abdominal cavity with bowel-to-sac adhesion as well as interloop adhesions. The hernia content was reduced, the oedema relieved and a protein mesh was placed to correct the hernia defect. The procedure was uneventful. No excessive bleeding was noted at the time of the procedure.

Post-surgery, the patient was hemodynamically stable. After recuperation for 4 days in the intensive care unit, the patient was discharged from the hospital. The patient was restarted on Pradaxa 110 mg for stroke prevention at the

time of discharge. A follow up after 7 days post discharge did not report any other significant finding and the patient was doing well on medication.



**Fig. 1:** Timelines for the case, from symptom onset to hospital discharge

## 3. Discussion

To the best of our knowledge, this is the first case of use of idarucizumab prior to emergency surgical intervention in India. Normal hemostasis was attained within 60 minutes of idarucizumab administration and was maintained throughout surgery. This was similar to what was observed in the RE-VERSE AD trial, wherein patients requiring emergency surgical interventions attained normal hemostasis in a median time of 1.6 hours. The post-operative hospital-stay was uneventful, and the patient was restarted on dabigatran on day 4 post-surgery.<sup>4</sup>

Papadopoulos et al reported a similar case in 2017 from Greece. They reported a case of NVAf on treatment with dabigatran presenting with right strangulated hernia with small bowel obstruction. Normal perioperative hemostasis within one hour of idarucizumab administration and a non-significant post-operative phase highlight the importance of a specific reversal agent in emergency situations. The patient was restarted on dabigatran at the time of discharge.<sup>5</sup> These two cases with similar timelines for intervention and restart of the drug would further enhance the confidence of physicians for the using idarucizumab to reverse the effect of dabigatran.

Fanikos et al in the RE-VECTO surveillance program looked at the real world use of idarucizumab. It was an observational study to evaluate the usage pattern of idarucizumab. Almost all of the 359 patients enrolled in the program were on the therapeutic on-label doses of dabigatran etexilate. The cases observed included cases of life threatening or uncontrolled bleeding and emergency surgeries. The surveillance program provides the usage pattern of idarucizumab, describing the indication as well as the dosage used. It showed that the real world scenarios of idarucizumab reflected the cases studied in the Phase III trial.<sup>6</sup>

Miller et al, and Salacki et al have reported the successful use of idarucizumab in patients requiring emergency cardiac tamponade and coronary artery bypass graft (CABG) with mitral valve annuloplasty respectively.<sup>7,8</sup> All these real

world cases of the use of idarucizumab for reversal of dabigatran anticoagulation prior to emergency surgeries would add to the results obtained from the RE-VERSE AD trial.

To conclude, it cannot be over-emphasized that with the advances in pharmaceutical medicine and availability of novel drugs, surgeons need to keep them abreast of basic knowledge about such newer drugs. At the same time, successful reversal of anticoagulation in real world would also enhance the confidence of physicians in using anticoagulants where indicated, without excessive fear of bleeding or need for emergency interventions.

#### 4. Conflict of Interest

The authors have no conflict of interest.

#### 5. Source of Funding

None.

#### References

1. Steffel J, Verhamme P, Potpara TS. European Heart Rhythm Association Practical Guide on the use of non-vitamin K antagonist oral anticoagulants in patients with atrial fibrillation. *Eur Heart J*. 2018;39(16):1330–93.
2. Keshishian A, Kamble S, Pan X, Mardekian J, Horblyuk R, Hamilton M, et al. Real-world comparison of major bleeding risk among non-valvular atrial fibrillation patients initiated on apixaban, dabigatran, rivaroxaban, or warfarin. *Thrombosis Haemost*. 2016;116:975–86. doi:10.1160/th16-05-0403.
3. Büller HR, Falanga A, Hacke W, Hendriks J, Lobban T, Merino J, et al. Managing reversal of direct oral anticoagulants in emergency situations. *Thrombosis Haemost*. 2016;116(12):1003–10. doi:10.1160/th16-05-0363.
4. Pollack C, Eikelboom J, Weitz J. Initial results of the RE-VERSE AD trial: Idarucizumab reverses the anticoagulant effects of dabigatran in patients in an emergency setting of major bleeding, urgent surgery or interventions. *Emerg Med J*. 2015;32(12). doi:10.1136/emered-2015-205372.9.
5. Papadopoulos A, Papadopoulos K, Balakera C, Chouliaras C, Katsaounis D, Kefalou E, et al. Use of idarucizumab for dabigatran reversal in patients with non-valvular atrial fibrillation undergoing emergency surgical repair of strangulated femoral hernia. *Hellenic J Surg*. 2017;89:117–20. doi:10.1007/s13126-017-0394-2.
6. Fanikos J, Murwin D, Gruenenfelder F. Global Use of Idarucizumab in Clinical Practice: Outcomes of the RE-VECTO Surveillance Program. *Thromb Haemost*. 2019;120(1).
7. Miller JD, Brinker JA, Spragg DD. First report of dabigatran reversal in iatrogenic pericardial tamponade during catheter ablation of atrial fibrillation. *Heart Rhythm Case Rep*. 2017;3:566–7. doi:10.1016/j.hrcr.2017.07.006.
8. Sałacki AJ, Zapolski T, Wysokiński A. Idarucizumab: a quick and effective antidote administered prior to coronary artery bypass surgery and mitral valve annuloplasty in a patient treated with dabigatran. *Polish Arch Int Med*. 2017;127:635–8.

#### Author biography

**Rajesh Badani**, Senior Consultant

**Annapurna Kalia**, Consultant

**Prakash Valse**, Senior Consultant

**Amod Tilak**, Medical Advisor

**Arun Kumar Dahiya**, Team Lead

**Cite this article:** Badani R, Kalia A, Valse P, Tilak A, Dahiya AK. Successful emergency surgery in a patient on dabigatran, after reversing the anticoagulation effect using Idarucizumab – A case report. *IP J Surg Allied Sci* 2020;2(4):120-122.