



Case Report

An effective and simple method for treatment of tongue thrusting in adult patient- A case report

Sanjana Shetty^{1,*}, Naazia Shaikh²

¹Dept. of Orthodontics and Dentofacial Orthopedics, Sinhgad Dental College and Hospital, Pune, Maharashtra, India

²Dept. of Orthodontics and Dentofacial Orthopedics, M.A. Rangoonwala College of Dental Sciences & Research Centre, Pune, Maharashtra, India



ARTICLE INFO

Article history:

Received 25-08-2021

Accepted 18-09-2021

Available online 11-02-2022

Keywords:

Tongue thrusting

Adults

Habit breaking appliance

ABSTRACT

Tongue thrusting is an aetiological factor in development of many malocclusions. This case report shows an effective method for correction of tongue thrusting in adults.

This is an Open Access (OA) journal, and articles are distributed under the terms of the [Creative Commons Attribution-NonCommercial-ShareAlike 4.0 License](https://creativecommons.org/licenses/by-nc-sa/4.0/), which allows others to remix, tweak, and build upon the work non-commercially, as long as appropriate credit is given and the new creations are licensed under the identical terms.

For reprints contact: reprint@ipinnovative.com

1. Introduction

The tongue is essential for several bodily functions, including swallowing, breathing, speaking, and chewing. Deglutition or swallowing is the act of moving food from the mouth to the stomach via the pharynx and oesophagus. Development of swallowing begins about 10-12 weeks after gestation. Full swallowing and suckling is established by 32-36 weeks of intra-uterine life.¹ Infantile swallow is characterized by active contractions of lip musculature and tip of the tongue is placed between the gum pads and the swallow is directed by the interplay of the tongue and the lips. Mature swallows develop between the ages of 4-5 years. Maturation of the swallow pattern occurs with the introduction of semisolid foods into the diet and the eruption of deciduous molars. It is distinguished by the relaxation of the lips, the positioning of the tongue behind the maxillary incisors, and the elevation of the jaw until the posterior teeth make contact.² A tongue thrusting habit occurs when the tongue makes contact with any teeth anterior to the molars during swallowing. Tongue thrust is

an oral behaviour pattern associated with the preservation of an infantile swallow pattern throughout infancy and adolescence. Forward tongue posture and tongue thrusting during swallowing are said to be the most common signs of tongue thrusting, as are hyperactive mentalis and orbicularis oris buccinator hyperactivity, and swallowing without the normal momentary tooth contact.^{3,4} While anterior location, excessive of the tongue has been associated with open-bite, other theories suggest that tongue pushing behaviour may be a consequence of an open-bite that, in fact, may enable an otherwise nonexistent oral seal.⁵⁻⁷ Tongue thrust has been associated to posterior crossbite, open bite, and excess overjet in terms of malocclusion.⁸ Treatment for tongue thrust differs according to the cause of the related issues. Habit breaking appliance becomes tedious to use for adult patients. This article shows a method that can be effectively used for correction of tongue thrusting in adults.

1.1. Case history

A 19-year-old female patient reported to the department with a chief complaint of forwardly placed front teeth. Patient does not give any significant family history, medical

* Corresponding author.

E-mail address: sanjanashetty816@gmail.com (S. Shetty).

history, dental history. Patient gave history of tongue thrusting habit. There were no findings on her fingers.



Fig. 1: Pre-treatment extra-oral photographs

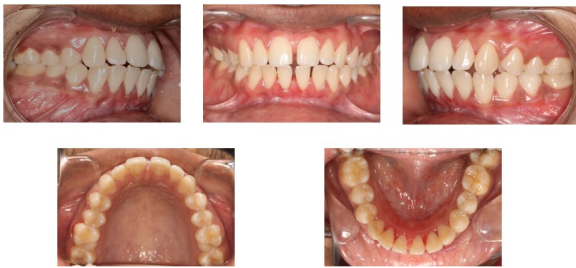

Fig. 2: Pre-treatment intra-oral photographs

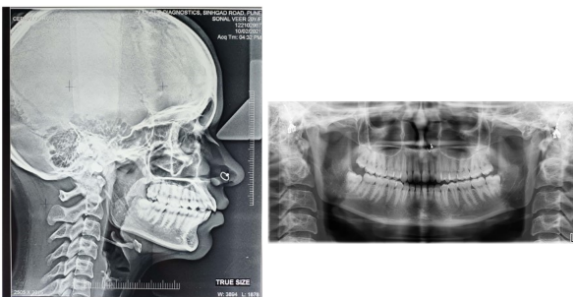


Fig. 3: Pre-treatment orthopantomogram and lateral cephalogram.

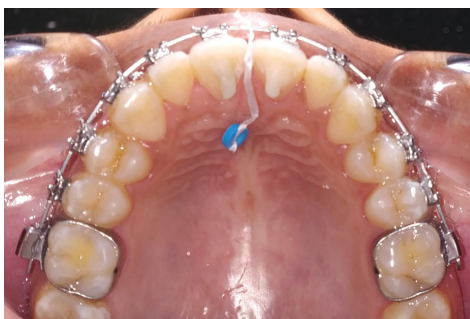

Fig. 4: Composite analysis of cephalometric findings

On extra oral examination patient was diagnosed with a mesoprosopic facial form, potentially incompetent lips and

Table 1: Composite analysis of cephalometric findings

Measurement	Mean	Pre RX
Skeletal		
SNA	82°	84°
SNM	80°	80°
ANB	2°	4°
Saddle angle	123+5°	125°
Gonial angle	142+5°	139°
Convexity at pt. A	2+2 mm	0mm
Facial Axis	90+3°	93°
Inferences-class II Skeletal Pattern		
Growth Pattern		
Go-Gn to Sn	32°	26°
FMA	25°	22°
Mandibular plane angle	26+4.5°	17°
Jaraback ratio	62-65%	70%
Inferences-Horizontal growth pattern		

Table 2: Composite analysis of cephalometric findings

Dental		
U1-NA angle	22o	30o
U1-NAmm	4mm	7mm
L1-NB angle	25°	38°
U1-NB mm	4mm	8mm
IMPA	90°	113°
Inferences-Proclined maxillary and mandibular incisors		
Soft tissue		
S line		
Upper lip	0mm	5mm
Lower lip	0mm	5mm
H line angle	7-15°	20°
Upper lip strain	2mm	4mm
Facial angle	90+3° 8	89°
Inferences-Protrusive upper and lower lips, increased lip strain		

convex profile. Smile arc is straight. Intra-oral examination shows spacing in maxillary and mandibular anteriors, class I incisor relationship, Class I canine and Class I molar relation on right side and end on canine and molar relation on left side.

Orthopantomogram examination shows normal condylar morphology bilaterally. All third molars are present and roots are still forming. The level of alveolar bone was normal years. On cephalometric examination, patient has Class II skeletal pattern, proclined maxillary and mandibular incisors, protrusive upper and lower lips, increased lip strain, horizontal growth pattern. Diagnosis- A 23 years old female patient is diagnosed with Class II skeletal pattern, average to horizontal growth pattern, Class I molar relation on left side, Class II molar relation on right side, class I canine relation on left side, Class II canine relation on right side Class I canine relation left side, class II division 1 incisor relation, proclined upper and lower incisors,

protrusive upper and lower lips, increased lip strain.

1.2. Treatment objectives

The main objective of the treatment was to eliminate the tongue thrusting habit which is aetiology of malocclusion here. The other treatment objectives were to improve the profile, lip competency, smile, to achieve normal overjet, overbite and correct proclination of maxillary and mandibular anteriors.

1.3. Treatment plan

Correction of tongue thrusting should be done along with commencement of fixed orthodontic treatment for correction of this malocclusion. Banding of all first molars should be done. A 0.022" slot preadjusted Edgewise appliance brackets with MBT prescription will be used in maxillary and mandibular arch. Extraction of all first premolars is planned after initial leveling and alignment with round NiTi wires, following sequence A of MBT. Use of 0.019/0.025" rectangular NiTi followed by 0.019/0.025" rectangular stainless steel wires for retraction and closure of spaces. Finishing and detailing will be done. Lingual bonded retainer will be given in both arches.

1.4. Treatment mechanics

Fixed orthodontic treatment was started according to the treatment plan. For tongue thrusting correction, spikes made of composite on the palatal side of upper central incisors were used so that patient does not thrust tongue between the teeth. With help of floss, an elastic module placed in between the central incisors. This will condition the patient to place tip of the tongue on palate behind the maxillary central incisors which is the normal tongue position.

2. Discussion

Comprehensive evaluation and treatment planning are required for successful orthodontic therapy.⁹ Dental malocclusion can be caused by a variety of environmental variables, including oral habits. The severity of a malocclusion caused by oral habits is determined by the frequency, duration, and intensity of the habit. These behaviours interfere with muscle balance and bone development, resulting in alterations to the dental arch and occlusal features.^{10,11} Hence, it is important to diagnose habits and correct them at appropriate time to avoid these harmful effects.

Tongue-thrust swallowing is described as the forward positioning of the tongue tip between the incisors during deglutition. Tongue thrusting is a behaviour in which the tongue makes contact with any teeth anterior to the molars when swallowing.¹² The most essential factor for correcting the tongue thrusting behaviour is to change the resting posture of the tongue. Orthodontic spikes, prongs, or other

tongue reminders, which correct the tongue rest posture and swallow, may be used to treat tongue thrust. The method used in this article is effective for redirecting tongue position with minimal discomfort to patient.

3. Conclusion

Abnormal tongue position in the context of an anterior open bite must be evaluated and corrected with care. Before using habit-breaking appliances, it is advised to begin with the least intrusive approaches, such as therapy and counselling. Correction of tongue thrusting is important for avoiding malocclusions it may cause. Redirecting tongue position with method used in this case report is effective in correcting tongue thrusting in adults.

4. Source of Funding

None.

5. Conflict of Interest

None.

References

1. Miller JL, Sonies BC, Macedonia C. Emergence of oropharyngeal, laryngeal and swallowing activity in the developing fetal upper aerodigestive tract: an ultrasound evaluation. *Early Hum Dev.* 2003;71(1):61–87. doi:10.1016/s0378-3782(02)00110-x.
2. Peng CL, Brinkmann PGJ. Comparison of tongue functions between mature and tongue-thrust swallowing-an ultrasound investigation. *Am J Orthod Dentofac Orthop.* 2004;125(5):562–70. doi:10.1016/j.ajodo.2003.06.003.
3. Hanson ML, Barnard LW, Case JL. Tongue-thrust in preschool children. *Am J Orthod.* 1969;56(1):60–9. doi:10.1016/0002-9416(69)90259-0.
4. Peng CL, Brinkmann PGJ, Yoshida N, Chou HH, Lin CT. Comparison of tongue functions between mature and tongue-thrust swallowing: An ultrasound investigation. *Am J Orthod Dentofacial Orthop.* 2004;125(5):562–70. doi:10.1016/j.ajodo.2003.06.003.
5. Lowe AA, Johnston WD. Tongue and jaw muscle activity in response to mandibular rotations in a sample of normal and anterior open-bite subjects. *Am J Orthod.* 1979;76(5):565–76. doi:10.1016/0002-9416(79)90260-4.
6. Wallen TR. Vertically directed forces and malocclusion: A new approach. *J Dent Res.* 1974;53(5):1015–37. doi:10.1177/00220345740530050101.
7. Cayley AS, Tindall AP, Sampson WJ, Butcher AR. Electropalatographic and cephalometric assessment of tongue function in open bite and non-open bite subjects. *Aust Orthod J.* 2000;16(1):23–33.
8. Subtelny JD. Examination of current philosophies associated with swallowing behavior. *Am J Orthod.* 1965;51:161–82.
9. Sinem T, Biren S, Ceylanoglu C. Tongue Pressure Changes Before, During and After Crib Appliance Therapy. *Angle Orthod.* 2010;80(3):533–72. doi:10.2319/070209-370.1.
10. Larsson E. Dummy- and finger-sucking habits with special attention to their significance for facial growth and occlusion. 4. Effect on facial growth and occlusion. *Svensk Tandlakare Tidskr Swed Dent. Swed Dent J.* 1972;65(12):605–39.
11. Frazao P, Narvai PC. Socio-environmental factors associated with dental occlusion in adolescents. *Am J Orthod Dentofacial Orthop.* 2006;129(6):809–16. doi:10.1016/j.ajodo.2004.10.016.

12. Falk ML. Neuromuscular facilitation for the control of tongue thrust swallowing. *Am J Orthod.* 1987;70(4):419–27. doi:10.1016/0002-9416(76)90114-7.

Naazia Shaikh, PG Student

Author biography

Sanjana Shetty, PG Student

Cite this article: Shetty S, Shaikh N. An effective and simple method for treatment of tongue thrusting in adult patient- A case report. *IP J Surg Allied Sci* 2021;3(4):116-119.