



## Case Report

# Disseminated, perforated gastrointestinal stromal tumour of small intestine with meckel's diverticulitis: A case report

Jyoti. S. Karegoudar<sup>1</sup>, Sharanappa Beragi<sup>1</sup>, Vijayanath V<sup>2,\*</sup>

<sup>1</sup>Dept. of General Surgery, Gadag Institute of Medical Sciences, Gadag, Karnataka, India

<sup>2</sup>Dept. of Forensic Medicine & Toxicology, ESIC Medical College & PGIMS, Bengaluru, Karnataka, India



### ARTICLE INFO

#### Article history:

Received 15-03-2022

Accepted 22-04-2022

Available online 31-05-2022

#### Keywords:

Gastrointestinal Stromal Tumour

GIST

perforated GIST

Meckel's diverticulitis

### ABSTRACT

A case of perforated gastrointestinal stromal tumour of small intestine with Meckel's diverticulitis causing acute abdomen is described, with a brief review of literature. A male patient presented with abdominal pain and distention, after evaluation, emergency laparotomy was done. The perforation of tumour in the ileum was found. The perforated part along with the tumour was resected and histopathological examination revealed that the tumour was gastrointestinal stromal tumour. Postoperatively the patient received Imatinib. Traditionally, the prognostic factors of these tumours are mitotic rate, tumour size and anatomic site. The complete surgical resection and use of Imatinib are the best approach.

This is an Open Access (OA) journal, and articles are distributed under the terms of the [Creative Commons Attribution-NonCommercial-ShareAlike 4.0 License](https://creativecommons.org/licenses/by-nc-sa/4.0/), which allows others to remix, tweak, and build upon the work non-commercially, as long as appropriate credit is given and the new creations are licensed under the identical terms.

For reprints contact: [reprint@ipinnovative.com](mailto:reprint@ipinnovative.com)

## 1. Introduction

Gastrointestinal stromal tumours (GISTs) are mesenchymal tumours arising in the gastrointestinal tract and occasionally in omentum, peritoneum and retroperitoneum. The incidence of GIST is very low accounting for 0.1-3% of all gastrointestinal tumours. Most common site is the stomach (60%), followed by the intestine (30%), while jejunal GIST is extremely rare.<sup>1</sup> GISTs are mostly seen in patients older than 50 years, with a male preponderance. Most GISTs clinically manifest as ill-defined abdominal pain, nausea, repeated vomiting, dyspepsia, obstruction, and gastrointestinal hemorrhage. Complete resection ensures better chances of survival. Imatinib, a tyrosine kinase inhibitor drug, has a major role to play postoperatively, since most GISTs are insensitive to chemo radiation.

## 2. Case Report

A 60 years old male patient came with history of mass per abdomen and pain abdomen. On examination abdomen was soft with generalized mild tenderness and mild guarding. CECT of abdomen was suggestive of neoplastic aetiology with probable diagnosis of gastrointestinal stromal tumour with multiple peritoneal metastasis with hollow viscus perforation (Figure 1).

Laparotomy revealed free fluid in the peritoneum with numerous nodules of variable sizes and consistency over the peritoneum, mesentery and ileum with some haemorrhagic nodules. Among them, one bigger nodule had ruptured and led to peritonitis and eventually sealed off by the omentum and coils of intestine. We also found unusual presence of Meckel's Diverticulum with gangrenous tip (Figure 2). Since the radical resection of all the nodules was impossible; only small segment of ileum including the ruptured bigger nodule with Meckel's Diverticulum was resected followed by ileo-ileal end-to-end anastomosis (Figure 3).

\* Corresponding author.

E-mail address: [drvijayanath@gmail.com](mailto:drvijayanath@gmail.com) (Vijayanath V).

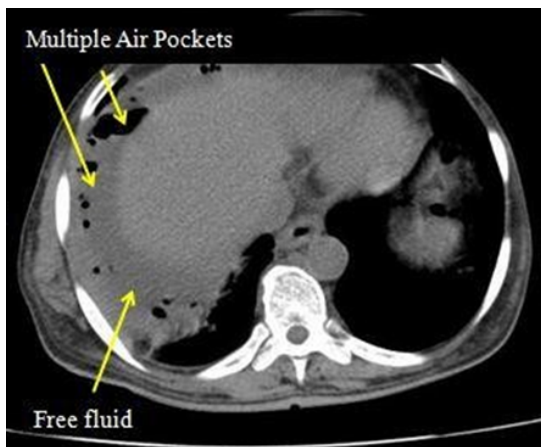


Fig. 1:

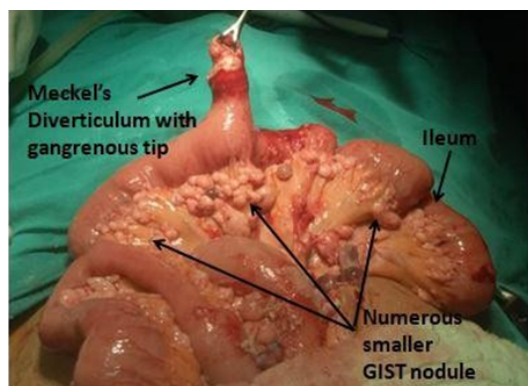


Fig. 2:

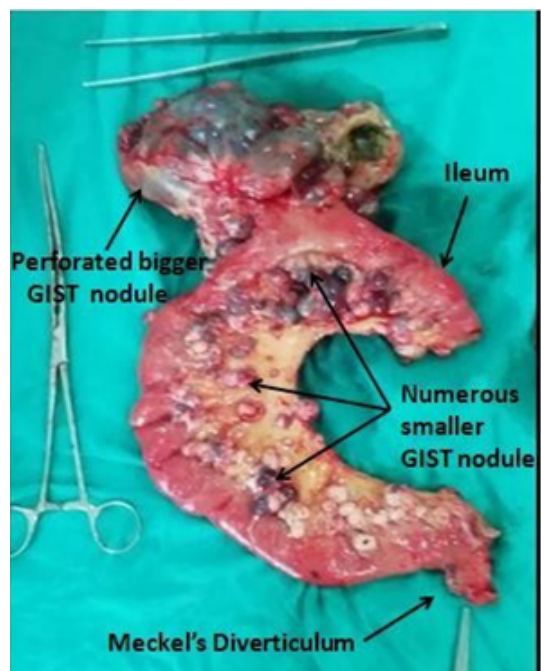


Fig. 3:

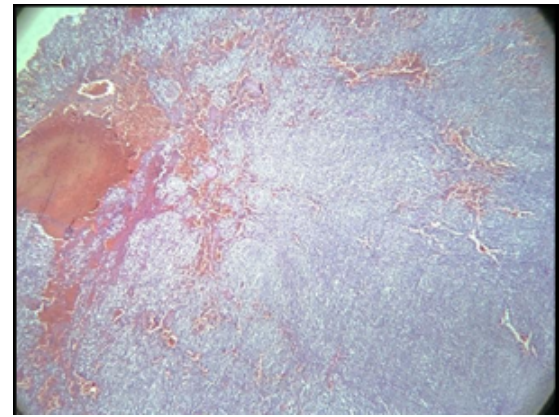


Fig. 4:

Histopathological examination of Cut section of nodule shows grey white to haemorrhagic areas with cystic changes (Figure 4). Our patient had an uneventful postoperative course and was discharged on 10<sup>th</sup> postoperative day. He was on tablet Imatinib 400 mg once a day. The follow up was done with CECT abdomen for 5 months, showing regression of nodules.

### 3. Discussion

GISTs are most common mesenchymal tumour of Gastrointestinal tract arising from smooth muscle pacemaker interstitial cells of Cajal.<sup>2</sup> The median age at diagnosis of GIST is 60 years.<sup>3</sup> They are equally common in men and women, and there is no racial or ethnic predilection. Most of the GIST arise in the stomach (70%), small intestine (20%), esophagus, colon, and rectum (<10%).<sup>1</sup> Occasionally, GISTs may arise in the duodenal ampulla, appendix, gallbladder, and urinary bladder. GIST can very rarely occur in Meckel's diverticulum.<sup>4</sup> In our case even though numerous GIST nodules were observed no single nodule was present in the Meckel's diverticulum instead we observed Meckel's diverticulitis with gangrenous tip. GISTs are usually solitary tumours. Multiple GISTs are extremely rare, except for in cases of Carney's syndrome, pediatric GIST, type 1 neurofibromatosis associated GIST, and familial GIST.<sup>5</sup> Of note, our patient presented with numerous nodules of variable sizes without such history. Small bowel GISTs have variable clinical presentations with vague abdominal pain being the most common symptom. Rarely present as a surgical emergency, such as intestinal obstruction, perforation or massive Gastrointestinal bleeding.<sup>1</sup> Prior to this indexed case, reviewing the current English literature revealed only 25 cases of acute abdomen due to spontaneous perforation of small bowel Gastrointestinal stromal tumour, indicating the rare incidence of such entity.<sup>6</sup>

Most GISTs have metastatic disease at diagnosis. Common sites of metastasis include liver, peritoneum, and omentum; lymph node metastases are rare. Extra abdominal metastases (lung, bone, subcutaneous tissues, and brain) are rare, observed in approximately 5% of patients.<sup>7</sup> In our case metastases were present over omentum and peritoneum.

The initial imaging study for a suspected or confirmed GIST is a CECT abdomen and pelvis.<sup>8</sup> Primary GISTs are typically well-circumscribed masses within the walls of hollow viscera. Magnetic resonance imaging (MRI) may help characterize metastatic liver or primary perirectal disease. Histologically, most cases fall into one of the following three categories — Spindle cell type-70%, Epithelioid type- 20%, mixed type- 10%. The best predictor of biologic behaviour is tumour size and mitotic count. In our case, the histological findings and biological predictor revealed spindle cell type and size of tumour more than 5cms and more than 5 mitosis per 50hpf suggestive of malignancy.

#### 4. Conclusion

GISTs are relatively rare and most of the time present with vague symptoms. Whenever patient presents with mass per abdomen and diffuse peritonitis, the possibility of ileal GISTs perforation to be considered, though it is extremely rare. Even with absence of GIST in the Meckel's diverticulum possibility of inflammation and gangrene of Meckel's diverticulum is also to be considered as observed with our case.

Early diagnosis with CECT abdomen, early surgical intervention, postoperative targeted molecular therapy and regular follow-up may lead to successful outcome.

#### 5. Source of Funding

None.

#### 6. Conflict of Interest

None.

#### References

1. Connolly EM, Gaffney E, Reynolds JV. Gastrointestinal stromal tumours. *Br J Surg.* 2003;90(10):1178–86. doi:10.1002/bjs.4352.
2. Kindblom LG, Remotti HE, Aldenborg F, Kindblom JMM. Gastrointestinal pacemaker cell tumour (GIPACT): gastrointestinal stromal tumours show phenotypic characteristics of the interstitial cells of Cajal. *Am J Pathol.* 1998;152(5):1259–69.
3. Dematteo RP, Lewis JJ, Leung D, Mudan SS, Woodruff JM, Brennan MF, et al. Two hundred gastrointestinal stromal tumours: recurrence patterns and prognostic factors for survival. *Ann Surg.* 2000;231(1):51–8. doi:10.1097/0000658-200001000-00008.
4. Chandramohan K. Gastrointestinal stromal tumour in Meckel's diverticulum. *World J Surg Oncol.* 2007;5:50.
5. Agaram NP, Laquaglia MP, Ustun B. Molecular characterization of pediatric gastrointestinal stromal tumours. *Clin Cancer Res.* 2008;14(10):3204–15. doi:10.1158/1078-0432.CCR-07-1984.
6. Khuri S, Hallon K, Azzam A, Kluger Y. Gastrointestinal Stromal Tumour of the Small Bowel: The Forgotten Cause of Massive Obscure Gastrointestinal Hemorrhage. *J Surg.* 2019;11:4–6.
7. Bertulli R, Fumagalli E, Coco P. Unusual metastatic sites in GIST [abstr 10566. *J Clin Oncol.* 2009;27(15):10566. doi:10.1200/jco.2009.27.15\_suppl.10566.
8. Demetri GD, Delaney T. NCCN: Sarcoma. *Cancer Control.* 2001;8(6):94–101.

#### Author biography

**Jyoti. S. Karegoudar**, Professor and HOD

**Sharanappa Beragi**, Assistant Professor

**Vijayanath V**, Professor and Head

**Cite this article:** Karegoudar JS, Beragi S, Vijayanath V. Disseminated, perforated gastrointestinal stromal tumour of small intestine with meckel's diverticulitis: A case report. *IP J Surg Allied Sci* 2022;4(2):56-58.