



Case Report

Endoscopic 270° subannular flap tympanoplasty: A case report

Amit Saini^{1,*}, R Abishek¹, Harjitpal Singh¹, Gaveshna Gargi¹

¹Dept. of Medicine, Dr Radhakrishnan Government Medical College, Hamirpur, Himachal Pradesh, India



ARTICLE INFO

Article history:

Received 08-12-2022

Accepted 17-12-2022

Available online 23-01-2023

Keywords:

Tympanoplasty

Endoscopic

ABSTRACT

Tympanoplasty performed using 270 degree subannular flap has shown better success rates. This technique is quite useful for large subtotal tympanic membrane perforations. This case report has successfully demonstrated the feasibility of performing this difficult surgical technique endoscopically and thus avoiding a post auricular scar and reducing morbidity to the patient.

This is an Open Access (OA) journal, and articles are distributed under the terms of the [Creative Commons Attribution-NonCommercial-ShareAlike 4.0 License](https://creativecommons.org/licenses/by-nc-sa/4.0/), which allows others to remix, tweak, and build upon the work non-commercially, as long as appropriate credit is given and the new creations are licensed under the identical terms.

For reprints contact: reprint@ipinnovative.com

1. Introduction

Tympanoplasty is the procedure of choice for managing patients with mucosal type of Chronic suppurative otitis media. Since its introduction by Wullstien tympanoplasty has undergone many changes. There are three main techniques of performing tympanoplasty namely underlay, overlay and interlay. In the underlay technique temporalis fascia graft is placed below the mucosal layer. The overlay technique involves removal of outer squamous layer and placement of graft over the fibrous layer. The interlay technique is another recent modification where graft is kept between squamous and fibrous layers.^{1,2}

The success of tympanoplasty depends upon many factors and important among these are graft placement and surgical technique. Posterior elevation of subannular flap is very an important step for successful placement of graft. Recently many surgeons have started elevating the subannular flap to 270degrees as it allows the surgeon to place the graft correctly and increases the success rate to 95 – 100%. In all these studies 270 degree subannular flap has been elevated by using surgical microscope through the post auricular route. In this case report the authors have

performed 270 degree flap tympanoplasty transmeatally using endoscope.^{3,4}

2. Case Report

Twenty five year old female patient visited the otolaryngology with complaints of decreased hearing from right ear. The otoscopic examination of the patient revealed subtotal perforation with minimal anterior margins. The pure tone audiometry was performed which showed 40 dB conductive hearing loss in right ear with normal hearing in left ear. Complete ENT examination was done and was found unremarkable. The patient was advised to undergo tympanoplasty through transmeatal or postauricular approach. The patient was willing to undergo tympanoplasty and requested for transmeatal route to avoid post auricular scar.

As the patient had minimal anterior margins the authors decided to perform 270 degree tympanomeatal flap tympanoplasty transmeatally using endoscope.

2.1. Surgical technique

The surgery was performed using 0 degree endoscope transmeatally. Temporalis fascia was used as graft material. The surgery was performed under local anaesthesia. The

* Corresponding author.

E-mail address: dr.saini@rediffmail.com (A. Saini).

margins of the perforation were incised with micro-sickle knife and under surface was freshened with micro-circular knife to remove the squamous epithelium. The tympanomeatal flap along with fibrous annulus was elevated 270 degree all around the bony canal while keeping the pars flacida and the anterior and posterior malleolar folds intact (Figure 1). The middle ear was filled with gelfoam and temporalis graft inserted behind the tympano-meatal flap and kept in the underlay technique. The part of the temporalis graft was firmly held between bony and fibrous annulus all around the tympanic membrane (Figure 2). After assuring stability of graft, the flap was repositioned and ear canal was filled with gelfoam.

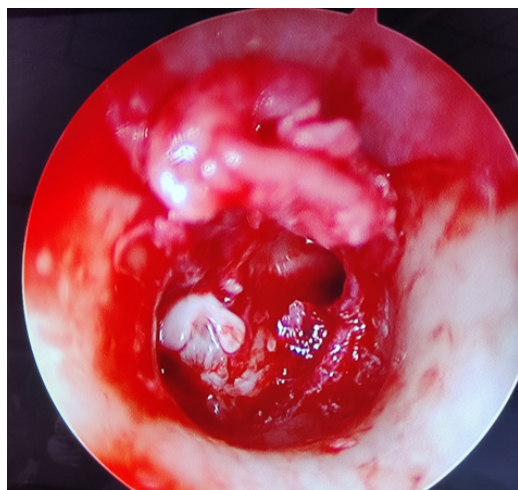


Fig. 1: 270° TM flap elevated endoscopically and reflected superiorly.

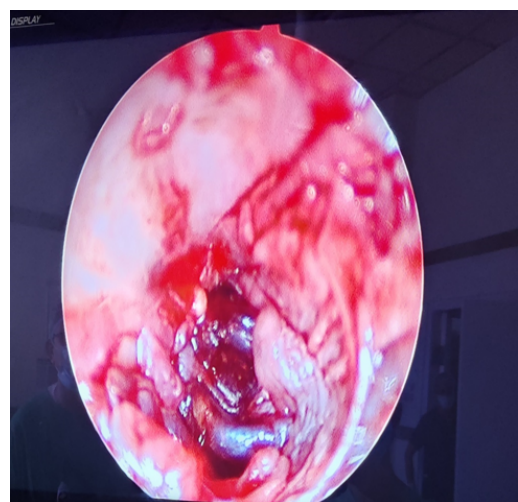


Fig. 2: Temporalis fascia graft placed and flap repositioned.

The patient was evaluated at 1,3 months and graft was found to be intact at the writing of this report.

3. Discussion

The circumferential subannular flap technique involves elevation of the whole of the fibrous annulus together with the tympanomeatal flap. The advantage of this technique is that the graft is not blindly tucked under the tympanic membrane remnant but directly over the bony annulus under vision. As it is a well-known fact that the blood supply to the tympanic membrane is circumferential and it has poor vascularity anteriorly when hence putting the graft under the annulus ensures adequate blood supply to the graft.

Study conducted by Ripu D. Arora et al; through same technique performed by post aural approach has shown a success rate of 95.1% in terms of graft uptake with significant air-bone gap closure after 12 month, without any complications like anterior blunting, lateralization or medialization of graft.⁵

Singh et al.⁶ have reported a success rate of 97.5% in graft uptake and significant hearing improvement using this technique. The success of this approach was attributed to the fibrous annulus holding the graft all around preventing the medialization and shrinkage of the graft.

A similar study with almost a similar technique conducted by Mokhtarinejad F et al showed a success rate of 97%. They also showed that underlay tympanoplasty with elevation of annulus away from the sulcus tympanicus anteriorly did not result in blunting and lateralization of the graft.³ However, blunting of the anterior tympanomeatal angle was seen in 9 patients in the study. Kartush J.M et al study on "Over-Under Tympanoplasty, wherein the graft was placed over the malleus and under the annulus, similar to our technique, reported late perforations in 12 patients out of 120 who underwent surgery.⁷

However all these studies have used the post aural approach. There is paucity of literature over use of endoscopes for performing 270° subannular flap tympanoplasty. This encouraged the authors to perform this procedure endoscopically.

4. Conclusion

The 270 degree tympanomeatal flap tympanoplasty has higher surgical success rate and is preferred in large subtotal perforations. This case report has demonstrated that 270 degree flap tympanoplasty can be performed transmeatally using zero degree endoscope.

5. Conflict of Interest

None.

6. Source of Funding


None.

References

1. Guneri A, Ecevit MC, Erdağ TK. Circumferential subannular grafting technique in tympanoplasty: preliminary results. *Kulak Burun Bogaz Ihtis Derg.* 2006;16(1):7-10.
2. Mishra P, Sonkhya N, Mathur N. Prospective study of 100 cases of underlay tympanoplasty with superiorly based circumferential flap for subtotal perforations. *Indian J Otolaryngol Head Neck Surg.* 2007;59(3):225-8.
3. Mokhtarinejad F, Okhovat SA, Barzegar F. Surgical and hearing results of the circumferential subannular grafting technique in tympanoplasty: a randomized clinical study. *Am J Otolaryngol.* 2012;33(1):75-9.
4. Singh GB, Ranjan S, Arora R. Role of circumferential subannular tympanoplasty in anterior and subtotal perforations. *J Laryngol Otol.* 2017;131(2):123-7.
5. Arora R, Thakur N, Kamble P, Jati M, Nagarkar NM, Thakur JS, et al. Circumferential subannular tympanoplasty: surgical and hearing outcome in 224 ears with subtotal perforation. *Acta Otolaryngol.* 2002;142(3-4):254-8. doi:10.1080/00016489.2022.2042596.
6. Singh GB, Dhawan R, Jha S. the concept of shrinkage of temporalis fascia graft. *J Otol Rhinol.* 2015;4(4):1-3. doi:10.4172/2324-8785.1000242.
7. Kartush JM, Michaelides EM, Becavarovski Z, Larouere MJ. Over-under tympanoplasty. *Laryngoscope.* 2002;112(5):802-7.


doi:10.1097/00005537-200205000-00007.

Author biography

Amit Saini, Assistant Professor  <https://orcid.org/0000-0002-1277-544X>

R Abishek, Medical Officer

Harjitpal Singh, Assistant Professor  <https://orcid.org/0000-0003-1377-0154>

Gaveshna Gargi, Assistant Professor  <https://orcid.org/0000-0001-9470-3353>

Cite this article: Saini A, Abishek R, Singh H, Gargi G. Endoscopic 270° subannular flap tympanoplasty: A case report. *IP J Surg Allied Sci* 2022;4(4):142-144.