



Case Report

Surgical management of an extensive admixed ameloblastoma involving the mandibular body

Jayant Landge¹, Vikas Meshram², Sanpreet Singh Sachdev^{3,*},
Prajwalit Prakash Kende¹

¹Dept. of Oral and Maxillofacial Surgery, Government Dental College and Hospital, Mumbai, Maharashtra, India

²Dept. of Oral and Maxillofacial Surgery, Trauma Care Unit, Medical College, Nagpur, Maharashtra, India

³Dept. of Oral Pathology and Microbiology, Government Dental College & Hospital, Mumbai, Maharashtra, India



ARTICLE INFO

Article history:

Received 20-10-2022

Accepted 05-11-2022

Available online 23-01-2023

Keywords:

Odontogenic Tumors

Segmental resection

Fibula graft

ABSTRACT

Admixed ameloblastoma comprises of a combination of more than one histomorphological patterns of ameloblastoma. The present case report discusses a case of admixed ameloblastoma extensively involving the entire body of the mandible bilaterally in a 25-year-old male. The case was managed by segmental resection using osteotomy to remove the segment of the mandible along with the right coronoid process. Histopathological examination of the excised tumor revealed highly proliferative odontogenic epithelium in the forms of plexuses and follicles. A fibula reconstructed graft was provided for rehabilitation of the patient with no evidence of disease after a one-year follow-up.

This is an Open Access (OA) journal, and articles are distributed under the terms of the [Creative Commons Attribution-NonCommercial-ShareAlike 4.0 License](https://creativecommons.org/licenses/by-nc-sa/4.0/), which allows others to remix, tweak, and build upon the work non-commercially, as long as appropriate credit is given and the new creations are licensed under the identical terms.

For reprints contact: reprint@ipinnovative.com

1. Introduction

Amongst the numerous entities described and periodically updated as OTs by World Health Organization (WHO),¹ approximately 40-50% (n=305,² n=250)³ of the OTs were found to be ameloblastoma (AM), making it the most common odontogenic neoplasm in India. The WHO in 2017,¹ defined AM as “a benign intraosseous progressively growing epithelial odontogenic neoplasm characterized by expansion and a tendency for local recurrence if not adequately removed.” The neoplasm is highly aggressive and may attain a very large size clinically, involving almost the entire jaw during its course.

The WHO recognizes follicular, plexiform, acanthomatous, desmoplastic, granular cell, and basaloid as histopathological variants of conventional AM without any clinical significance.¹ Occasionally, a combination of

two or more histomorphological patterns can be noted and these have been described as ‘admixed AM’ in the WHO classification of head and neck tumors.^{1,4} Even so, surgical excision with an adequate margin or radical resection is considered as the treatment of choice for AM, regardless of its histopathological variant.

The present case report describes the management of one such case of admixed AM involving most of the body of the mandible in a young adult male.

2. Case Report

A 25-year-old male complained of a swelling involving most of his lower jaw region since three years. A history of trauma to the lower anterior region four years ago. Spontaneous exfoliation of the mandibular central incisors and mandibular left first molar had occurred one year ago. The swelling had gradually increased to its present size over the past year. The patient’s medical and family history was non-contributory.

* Corresponding author.

E-mail address: sunpreetss@yahoo.in (S. S. Sachdev).

Extraorally, diffuse swelling of approximately 9 x 4 cm was noted involving the lower one-third of the face. It extended from the angle of the mandible on the right side to 1 cm in front of the angle on the left side. On palpation, the swelling was non-tender, and hard in consistency without any noticeable crackling. The lower border of the mandible was traceable throughout its perimeter on palpation.

Intraorally, an intraosseous swelling extending from the mandibular left second premolar to the mandibular right second molar was noted. Gross expansion of buccal and lingual cortical plates of the mandibular anterior region between both the lower canines was present. The mandibular right lateral incisor was severely displaced distally. Grade II mobility was observed bilaterally with the mandibular canines and first premolars. Significant thinning of the inferior border of the mandible was noted.

Orthopantomogram revealed a multilocular radiolucent lesion extending from the distal of the mandibular right third molar to the left third molar. Resorption of roots of the mandibular left first and second molars was noted. The inferior alveolar canal was non-traceable. A provisional diagnosis of ameloblastoma was considered; while the differential diagnosis included odontogenic keratocyst and malignant odontogenic tumors.

Multi-slice Computed Tomography Scan of Head and Neck showed a large, multicystic, expansile lesion with a soap-bubble appearance involving the entire mandibular body till the angle of the mandible on both sides.

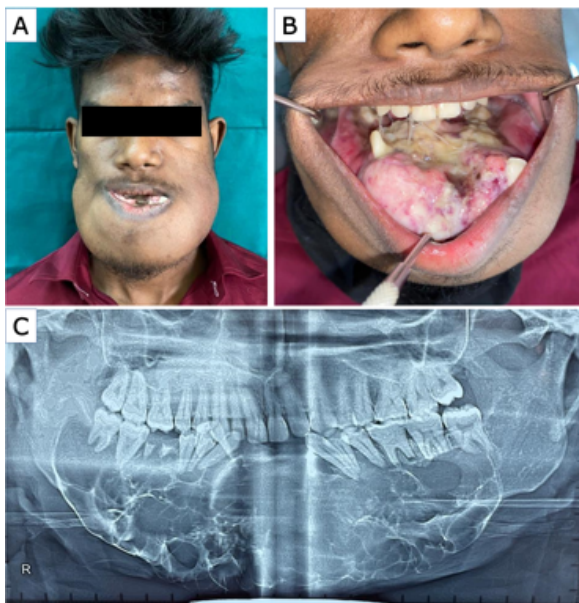

Fig. 1: Diffuse swelling involving the entire body of the mandible noted A) Extra-orally, and B) Intra-orally. C) Orthopantomogram exhibiting an expansile multilocular lesion with extreme thinning of the inferior border of the mandible.

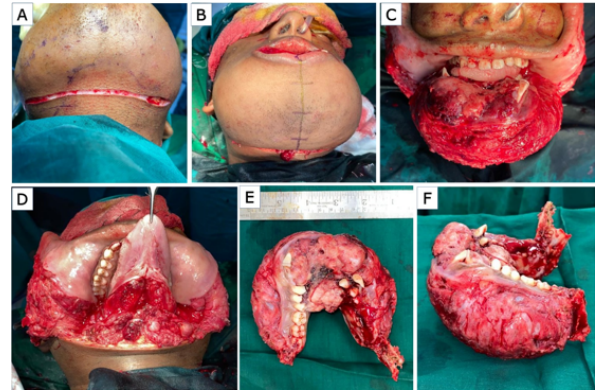


Fig. 2: A) Trans-cervical incision; B) Lip-split procedure; C) Complete exposure of the lesion; D) Site of surgery after resection; E) and F) Resected segment of the mandible with the tumor mass

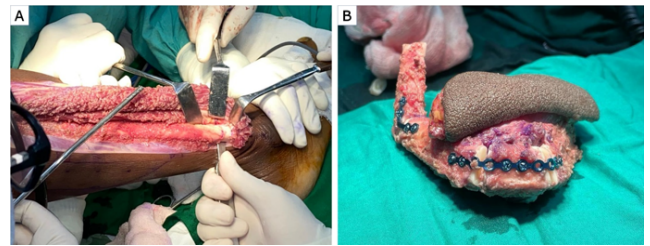


Fig. 3: A) Harvesting of the fibula graft; B) Fibula graft-reconstructed mandible

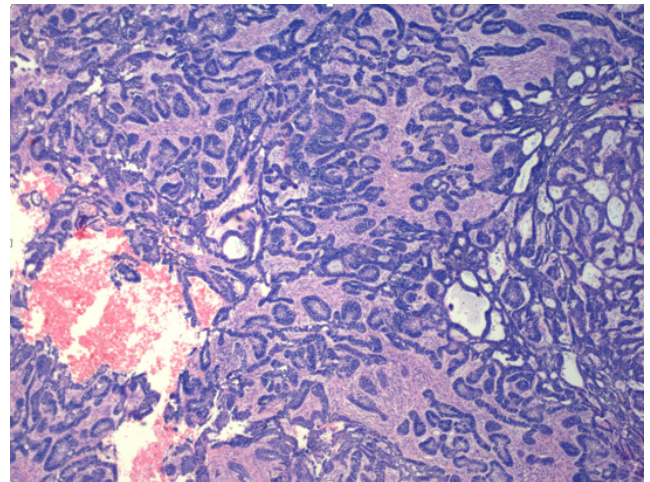


Fig. 4: Histopathological presence of hyperchromatic odontogenic epithelium in the form of abundant follicles as well as plexuses (H and E, Original Magnification x 40)

Multiple cortical defects were noted along the buccal and lingual cortices of the mandible. Internal soft tissue (35 HU) showed strong post-contrast enhancement (103 HU). No evidence of any other significant findings was noted elsewhere in the brain, head or neck. The lesion was diagnosed as AM on incisional biopsy.

Under general anesthesia and aseptic conditions, a tracheostomy procedure was performed. A trans-cervical incision was given 1 cm below the inferior border of the mandible along the neck crease followed by a lip split for extraoral exposure of the lesion. Additionally, a trans-oral vestibular incision was given from the mandibular left first molar to right first molar region. Dissection was done to expose the lesion by extending the incision along the anterior border of the ramus up to the level of the upper molar.

Osteotomy was performed distal to mandibular left third molar and in the right ramus region preserving the condyle. The segment of the mandible along with the right coronoid process was removed. The bleeding vessels were cauterized and hemostasis was achieved. The surgical area was packed with wet gauze with 1% povidone iodine to achieve hemostasis. Rehabilitation of the patient was done with a free fibula graft reconstruction.

Histopathological examination of the excised tumor revealed highly proliferative odontogenic epithelium in the forms of plexuses and follicles. These structures were lined peripherally by hyperchromatic, tall columnar ameloblast-like cells exhibiting reversal of nuclear polarity. Centrally, loosely-cohesive stellate reticulum-like cells were noted. The intervening connective tissue stroma was mature and fibrous consisting of dense bundles of collagen fibers interspersed with fibroblasts. Areas of cystic degeneration were noted in some of the plexuses and follicles. Given the abundance of both, the plexiform as well as the follicular patterns, a final diagnosis of ‘admixed ameloblastoma’ was imparted.

A one-year follow-up has shown that the patient has well-adapted to the treatment with no evidence of disease or recurrence.

3. Discussion

The perforation of buccal cortical plates throughout the mandible and the lingual cortical plate in the mandibular anterior region corresponds to the vulnerability and density patterns of the alveolar bone in these regions.⁵ The incisors, canines and premolars on both the sides exhibited distal tipping indicative of epicenter of the lesion in the mandibular anterior region. Generally, lingual cortical plates in the mandibular posterior region are extremely dense and are rarely perforated unless the tumor is malignant and highly aggressive.

The differential diagnosis in the present case, considered second to AM was OKC. OKCs tend to attain a large size as the cystic lining spreads through the medullary

spaces in an anteroposterior direction. However, it has been demonstrated that OKCs seldom cause root resorption,⁶ which was noted with the molars in our case.

The other differential diagnosis, malignant odontogenic tumors, are quite rare in incidence. Given the duration of the lesion of more than three years in our case, a malignant tumor would have caused much more rampant destruction of local structures and possibly, even metastasis.¹ Furthermore, had it been a malignant tumor, perforation of the cortices and the inferior border of the mandible would have readily occurred before the lesion attained its present size. An intact, traceable inferior border of the mandible on palpation pointed towards a benign entity. Nevertheless, the possibility of a benign tumor transforming into a malignant one could not be overlooked.

Clinicodemographic studies pertaining to AM have reported that 7-20% of cases may exhibit admixed histopathological types.^{4,7} Unpublished data from one of our researches has also found 14% of AMs to comprise of mixed histomorphological patterns. The number may actually be higher, as pathologists generally tend to assign the pattern observed predominantly on microscopic examination. Even so, identifying or assigning histopathological variants to AM is mostly of academic interest and does not have a direct implication on the clinical course and outcome.

4. Conclusion

Meticulous clinical and radiographic analysis helps in distinguishing AM from its other differential diagnosis. Management of AM becomes extremely challenging when the tumor attains a size large enough to involve a major portion of the jaws. Adequate surgical resection followed by replacement of the lost masticatory apparatus by appropriate means enables a faster rehabilitation for the patient; ultimately improving their quality of life.

5. Source of Funding

None.


6. Conflict of Interest


None.


References

1. Takata T, Slootweg PJ, El-Naggar AK, Chan JK, Grandis JR, Takata T. Odontogenic and maxillofacial bone tumours. In: and others, editor. WHO Classification of Head and Neck Tumours.; 2017.
2. Deepthi PV, Beena VT, Padmakumar SK, Rajeev R, Sivakumar R. A study of 1177 odontogenic lesions in a South Kerala population. *J Oral Maxillofac Pathol.* 2016;20(2):4989547. doi:10.4103/0973-029X.185897.
3. Sriram G, Shetty RP. Odontogenic tumors: a study of 250 cases in an Indian teaching hospital. *Oral Surg Oral Med Oral Pathol Oral Radiol Endod.* 2008;105(6):14–21.

4. Hertog D, Bloemena E, Aartman IH, Van-Der-Waal I. Histopathology of ameloblastoma of the jaws; some critical observations based on a 40 years single institution experience. *Med Oral Patol Oral Cir Bucal* . 2012;17(1):76–82.
5. Kim JH, Park YC. Evaluation of mandibular cortical bone thickness for placement of temporary anchorage devices. *Korean J Orthod*. 2012;42(3):110–7.
6. Martins GG, Oliveira IA, Consolaro A. The mechanism: how dental resorptions occur in ameloblastoma. *Dental Press J Orthod*. 2019;24(4):21–32.
7. Patsa S, Jadav RB, Halder GC, Ray JG, Datta S, Deb T. Demographic and histopathological variation of ameloblastoma: A hospital-based study. *J Oral Maxillofac Pathol*. 2016;20(2):230–3.

Vikas Meshram, Associate Professor  <https://orcid.org/0000-0003-4052-707X>

Sanpreet Singh Sachdev, Post Graduate  <https://orcid.org/0000-0001-7655-8180>

Prajwalit Prakash Kende, Professor and Head  <https://orcid.org/0000-0001-5688-6371>

Cite this article: Lande J, Meshram V, Sachdev SS, Kende PP. Surgical management of an extensive admixed ameloblastoma involving the mandibular body. *IP J Surg Allied Sci* 2022;4(4):156-159.

Author biography

Jayant Lande, Associate Professor  <https://orcid.org/0000-0002-1913-1401>