

Content available at: <https://www.ipinnovative.com/open-access-journals>

IP Journal of Surgery and Allied Sciences

Journal homepage: <https://www.jsas.co.in/>

Original Research Article

To identify the risk factors of sigmoid volvulus in central India tribal area population

Atul Kumar Khare¹, Dhananjay Majhi², Kuldip Pratap Patel^{1,*}¹Dept. of General Surgery, GMC Shahdol Medical College and Hospital, Madhya Pradesh, India²Dept. General Surgery, Government Medical College, Ratlam, Madhya Pradesh, India

ARTICLE INFO

Article history:

Received 05-04-2023

Accepted 22-04-2023

Available online 15-05-2023

Keywords:

Sigmoid colon

Strangulation

Volvulus

ABSTRACT

Background: Sigmoid volvulus is a condition in which the torsion of the sigmoid colon around its mesenteric axis leads to acute colonic obstruction that is not timely and properly treated, leading to life-threatening and morbid complications such as bowel ischemia, gangrene and perforation. The aim of the study is to analyze the risk factor of SV, clinical signs and symptoms, treatment, complications and outcomes when it presents as a surgical emergency in a tribal area in central India.

Materials and Methods: This is a prospective, single-center, cohort study of 24 patients presenting to the government with features of SV, medical college Shahdol [tribal area of central India] from June 2022 to November 2022. All data formulated in frequency charts.

Results: We develop a prediction model for the high incidence of SV, its presentation and treatment in patients from the trunk region. 21 patients (87.5%) were male and 3 patients (12.5%) were female. The age of the patients varied between 30-80 years, most of them between 50-70 years. The main risk factors were [1] old age, [2] male gender, [3] rural residence, [4] low socioeconomic status, [5] pure vegetarian diet, [6] abuse [mc-alcohol], [7] chronic constipation, [8] chronic pain medication user [9] associated comorbidity [mc-hypertension] [10] high fiber diet, have a higher chance of this. The most common symptoms were absolute constipation and generalized abdominal distension followed by abdominal pain. The most common symptoms were tenderness followed by tachycardia and then fever. All patients were examined by clinical symptoms, plain X-ray of the upright abdomen and blood tests. Vomiting, the most common postoperative complication, followed paralytic ileus. Among the patients, 6 had distended gangrenous SV, 15 patients were found to have distended non-gangrenous, and 3 patients had perforated gangrenous sigmoid colon volvulus. Mostly treated with sigmoidectomy with stoma followed by resection with colorectal anastomosis with flatus bypass. Most patients were discharged, only 3 [12.8%] patients died.

Conclusions: SV predominates in older men. Most patients with SV have a history of alcohol abuse, a high-fiber diet, and low socioeconomic status.

This is an Open Access (OA) journal, and articles are distributed under the terms of the [Creative Commons Attribution-NonCommercial-ShareAlike 4.0 License](https://creativecommons.org/licenses/by-nc-sa/4.0/), which allows others to remix, tweak, and build upon the work non-commercially, as long as appropriate credit is given and the new creations are licensed under the identical terms.

For reprints contact: reprint@ipinnovative.com

1. Introduction

Sigmoid volvulus is a condition in which torsion of the sigmoid colon around its mesenteric axis, which leads to acute large bowel obstruction, which not

treated timely and properly, leads to life-threatening and morbid complications, like bowel ischemia, gangrene and perforation and also death.^{1,2} so required early and correct diagnosis which is very essential for proper and timely treatment, which is required to correcting abnormal pathophysiological changes and restoring intestinal changes which is caused by the volvulus. Elderly, hospitalized

* Corresponding author.

E-mail address: mgmatulkhare92@gmail.com (K. P. Patel).

patients and neurogenic disorders peoples are mainly affected. Emergency surgery is mainly done for those peoples who present with diffuse peritonitis, intestinal perforation or ischemic necrosis.^{3,4} Colonoscopy used to evaluation of colonic mucosa [presence or absence of signs of ischemia].^{5,6}

The cause of SV is not known clearly. Main risk factors are long congenital sigmoid with a short mesenteric base, chronic constipation, high fibre diet, acquisitive mega colon, uses of anticholinergic drugs, sedatives and anti-Parkinson agents.⁷ Rotation of bowel always occurs in an anticlockwise and 180 degrees for complete rotation.⁸ SV is a very good example of closed loop obstruction. If the ileo-caecal valve is competent, a double closed loop obstruction developed and this result with huge distention of bowel.^{9,10}

Clinical features are abdominal pain, constipation and abdominal distention. elderly peoples who consuming psychotropic medications, pain is not common features, such patients mainly significant abdominal distention.¹¹ diagnosis made by abdominal X-ray, enema, sigmoidoscopy, CT- scan and blood test.¹²⁻¹⁶

2. Materials and Methods

This is a prospective cohort study of 24 patients presented with the features of SV to govt. medical college Shahdol [tribal area of central India] from June 2022 to December 2022. We studied the causes of high incidence of SV, clinical features, management, complication and outcomes.

All suspected cases presented to casualty or outpatient, included in this study. Patients who present with other surgical emergencies and bowel perforation were excluded.

In data we included- age, sex, residency, socio-economic status, diet pattern, abuse, comorbidity, past history, clinical presentation, diagnostic and therapeutic measures, post-operative complications and outcomes were recorded. All data were recorded with frequency and percentage and presented in frequency tables.

3. Observation and Results

In our study, 24 patients presented with the clinical features of SV.

There were 21 (87.5%) male and 3 (12.5%) female patients, with the male to female ratio was 7:1.

The age distribution ranged from 30-70 years. The highest incidence was in the 50-70 years age group, in which 16 patients (66.6%).

Most patients are coming from rural area 22 [91.6%] with low socioeconomic status.

Most patients have pure vegetarian 18 [75%] consume high fibre rich diet.

Most commonly abused material ganja 20 [80%], alcohol 18 [75%], and tobacco 18 [75%] peoples.

Most common comorbidity is hypertension 14 [58.3%], hypertension with diabetes 10 [41.6%], diabetes 8 [33.3%], anaemia 7 [29.1%], hepatitis 4 [16.6%] and tuberculosis 2 [8.33%].

19 patients (79.1%) gave history of chronic constipation, 12 patients [50%] consumes high fibre diet, 3 patients (12.5%) were hospitalised with neuropsychiatric disorder, 2 patients [8.3%] have bed ridden due to previous surgery.

Table 1: Demographic factors

Parameter	Sigmoid volvulus Cases	Percentage
Age		
≤30y	0	0
30-50y	4	16.66
50-70Y	16	66.66
≥70y	4	16.66
Sex		
Male	21	87.5
Female	3	12.5
Residency		
Rural	22	91.6
Urban	2	8.3
Diet		
Pure vegetarian	18	75
Mixed	6	25
Abuse		
Alcohol	18	75
Ganja	20	80
Tobacco	18	75
Socioeconomic status		
Low	22	91.6
Lower-middle	1	4.2
Middle	1	4.2
Comorbidity		
Hypertention	14	58.3
Diabetic	8	33.3
Hepatitis-b	4	16.66
Tuberculosis	2	8.33
Htn+dm	10	41.6
Anemia	7	29.1

In our study, the main presenting symptoms were constipation and abdominal distension 23 patients (95.8%) followed by abdominal pain 21 [87.5%] and vomiting 22 (41.6%) patients. Main signs are tenderness 87.5%, tachycardia 83.3%, icterus 41.6%, respiratory distress and oliguria 12.5% cases.

Investigated by plain abdominal X-ray and blood investigations done in all patients. Which showed characteristic features of sigmoid volvulus in 18 patients (75%), like- omega sign of the dilated colon [apex of the loop under the left hemidiaphragm and the convexity of the loop points towards the right upper quadrant], 3 (12.5%) showed distended ileal loops in a distended sigmoid colon and 3 patient (12.5%) showed free air under left hemi

Table 2: Clinical sign and symptoms

Parameter	Frequency	Percentage
Symptoms		
Abdominal distension	23	95.8
Constipation	23	95.8
Abdominal pain	21	87.5
Vomiting	10	41.6
Fever	12	50
Sign		
Tenderness	21	87.5
Tachycardia	20	83.33
Icterus	10	41.6
Respiratory distress	3	12.5
Oliguria	3	12.5

diaphragm.

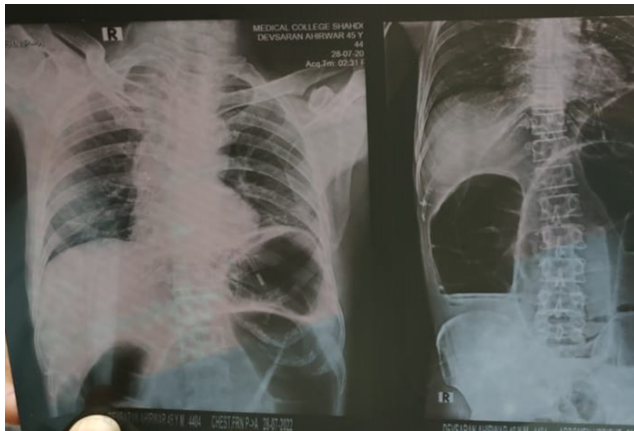


Fig. 1: X-Ray of sigmoid volvulus

On blood investigations, 20 patients (83.3%) had leucocytosis [16 of them have a WBC count >16000\cc, while 4 patients (16.7%), the WBC count less than 16000\cc]. Leucocytosis more than 16000\cc in 16 of the patients, 5 patients underlying strangulation and gangrene and 2 patients perforated. 10 patients [42.3%] was anaemic. 50% patients found hypokalaemia S. potassium less than 3.4 mg/dl.

All patients who were suspected clinically that, have an underlying strangulation, doing emergency exploratory laparotomy. 6 cases (25%) have intraoperatively found gangrenous bowel found. No patient managed by nonoperative management. The majority of these cases were managed by sigmoidectomy with colostomy/ileostomy in patients who had found gangrenous sigmoid colon or a sigmoid colon with questionable viability intraoperatively, after operative detorsion (17 patients, 70.83%).

In our study Paul-Mikulicz procedure was done in only 1 patient [4.1%]. New surgical modification technique Sigmoidectomy and colorectal anastomosis bypassing flatus tube was done in 6 patients (25%) and thus bypassing the

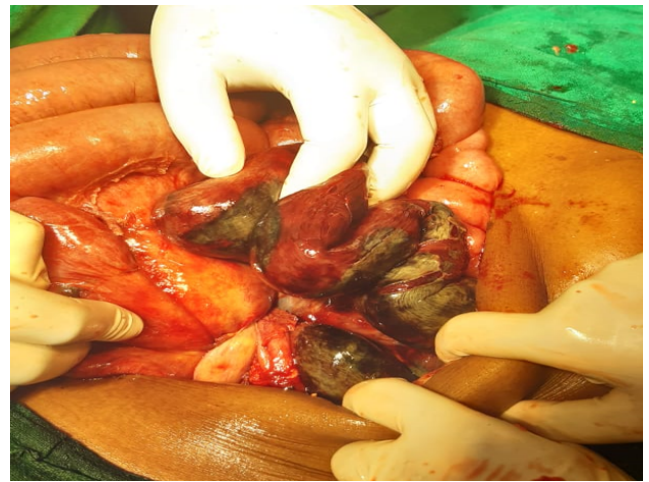


Fig. 2: Intraoperative finding- gangrenous colon

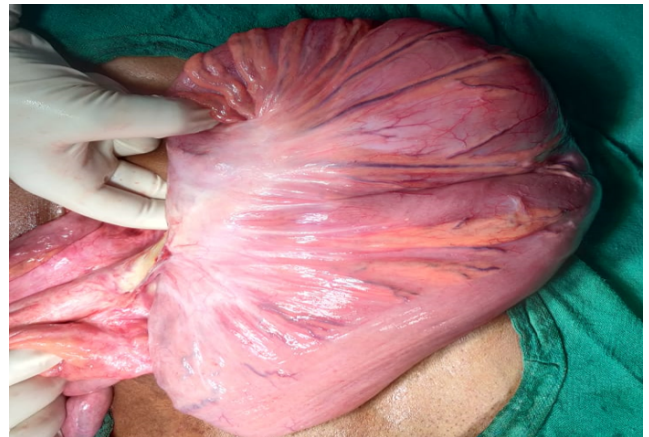

Fig. 3: Intraoperative finding- large colonic distension

stoma formation and future stoma closure.

Table 3: Treatment and complications

Treatment Sigmoidectomy with RA with ileostomy	17	70.83
Sigmoidectomy with colorectal Anastomosis by passing flatus tube Paul-miculicz	6	25
Complications Postoperative vomiting	1	4.2
Anastomotic leak	8	33.33
Paralytic ileus	4	16.66
Pbstruction	6	25
Outcomes Discharge	4	16.66
Death	21	87.5
	3	12.5

Most common post-operative complications are vomiting [33.3%], paralytic ileus [25%], anastomotic leak and obstruction [16.66%]. Majority of patients discharged

[87.5%] and 12.5% patients died.

4. Results and Discussion

Osime U et al done a prospective cohort study of 25 patients, in patient with features of strangulated sigmoid colon volvulus. This study done in Al-Karama Teaching Hospital (surgical casualty) from March 2014 to March 2018. In this study 18 patients (72%) were males and 7 patients (28%) were females. The age ranged from 20-70 years. The main predisposing/risk factor were chronic constipation, laxative dependency and high fibre diet. The most common presenting symptoms and signs were absolute constipation, abdominal distension, tenderness, tachycardia and fever.¹⁷

In our study 21 patients (87.5%) were males and 3 patients (12.5%) were females. The age of the patients ranged from 30-80 years most of them ranged between 50-70 years. The main risk factor was¹ old age,² male sex,¹¹ rural residency,¹⁸ low socioeconomic status,³ pure vegetarian diet,⁴ abuse [mc- alcohol],¹⁹ chronic constipation,²⁰ chronic pain killer user⁵ associated comorbidity [mc- hypertension][10] high fibre diet has more chances of this.

In our study the most common presenting symptoms were absolute constipation and generalized abdominal distension followed by abdominal pain. Most common signs were tenderness followed by tachycardia and then fever. All the patients were investigated by clinical symptoms, plain abdominal erect X-ray and blood investigations

Friedman et al, studied that, as sigmoid volvulus is a disease which is associated with high morbidity and mortality and high recurrence following non-operative decompression or non-operative line of management, therefore in all patient's definitive surgery is required.²¹ Similarly Mokoena TR et al, studied in 90 cases of sigmoid volvulus and advocate that resection in all patients.²² Similarly Baker DM et al, saying that, a colostomy rather than primary anastomosis is indicated if emergency surgery done.²³

In our study vomiting most common postoperative complication followed paralytic ileus. Among the patients, 6 had distended gangrenous SV, 15 patients were discovered to have distended non-gangrenous and the 3 patients had a perforated gangrenous sigmoid colon volvulus. Mostly treated by sigmoidectomy with stoma followed by resection with colorectal anastomosis bypassing flatus tube.

Bagarani M et al, also saying that, resection with primary anastomosis in patients with viable colon and colostomy in patients with strangulated colon, the treatment of choice in sigmoid colon volvulus.²⁴ the morbidity and mortality rates were highest in strangulation patients (16%) and the latter was (4%). There are nearly similar results are found to other studies:

Mokoena et al, also reported a (20%) morbidity rate and (12%) mortality rate, there are mostly of which was in the

emergency operating group.²² similarly Osime U, studied that a (7.9%) mortality rate after resection of strangulated sigmoid colon volvulus.¹⁷

In our study 12.5% patients' death and most of the patients discharged.

5. Conclusion

SV is more common in males. Middle-old age individuals found most affected group.in the study Majority of patients with SV was [1] old age, [2] male sex, [3] rural residency, [4] low socioeconomic status, [5] pure vegetarian diet, [6] abuse [mc- alcohol], [7] chronic constipation, [8] chronic pain killer user [9] associated comorbidity [mc- hypertension] [10] high fibre diet. The main presenting symptoms and signs of patients are abdominal distension and tenderness, tachycardia and fever with abdominal distension and absolute constipation. All the patients were investigated by clinical symptoms, plain abdominal erect X-ray and blood investigations. Vomiting most common postoperative complication followed paralytic ileus. Among the patients, 6 had distended gangrenous SV, 15 patients were discovered to have distended non-gangrenous and the 3 patients had a perforated gangrenous sigmoid colon volvulus. Mostly treated by sigmoidectomy with stoma followed by resection with colorectal anastomosis bypassing flatus tube. Majority of patients discharged, only 3 [12.8%] patient died.

6. Source of Funding

None.

7. Conflict of Interest

None.

References

1. Katsikogiannis N, Machairiotis N, Zarogoulidis P, Sarika E, Stylianaki A, Zisoglou M. Management of sigmoid volvulus avoiding sigmoid resection. *Case Rep Gastroenterol.* 2012;6(2):293-9.
2. Raveenthiran V. Observations on the pattern of vomiting and morbidity in patients with acute sigmoid volvulus. *J Postgraduate Med.* 2004;50(1):27-9.
3. Suleyman O, Kessaf AA, Ayhan KM. Sigmoid volvulus: long-term clinical outcome and review of the literature. *South Afr J Surg.* 2012;50(1):9-15.
4. Coban S, Yilmaz M, Terzi A, Yildiz F, Ozgor D, Ara C. Resection and primary anastomosis with or without modified blow-hole colostomy for sigmoid volvulus. *World J Gastroenterol.* 2008;14(36):5590.
5. Turan M, Sen M, Karadayi K, Koyuncu A, Topcu O, Yildirim C. Our sigmoid colon volvulus experience and benefits of colonoscope in detortion process. *Rev Española Enfermedades Diges.* 2004;96(1):32-7.
6. Martínez DA, Yáñez JL, Souto JR, Vázquez MM, González BC, Suárez FL. Indication and results of endoscopic management of sigmoid volvulus. *Rev Esp Enferm Dig.* 2003;95(8):544-52.
7. Fry RD, Mahmoud N, Maron DJ, Ross HM, Rombeau J. Townsend CM, eds. Sabiston Textbook of Surgery. 18th ed. and others, editor.

- Philadelphia: WB-Saunders; 2003. p. 1364–9.
8. Mann CV. Bailey and Love's Short Practice of Surgery. Mann C, Russell R, William NS, editors. Chapman-Hall; 1995. p. 820–1.
 9. Bortolo DC, Johnston JM, Macleod IB, Rintoul RF. Operations on the intestine: volvulus of the colon. In: Rintoul RF, eds. Farquharson's Textbook of Operative Surgery. 8th ed. and others, editor. Churchill Livingstone; 1995.
 10. Schrock TR. Large intestine volvulus. In: Way LW, eds. Current surgical diagnosis and treatment. USA, Prentice; Hall-International-AppletonLange; 1988. p. 614–6.
 11. Konder JJ, Fry RD, Fleshman JW, Galloway AC, Schwartz SI, Fischer JE. Principle of Surgery. Scharwtz, of Surgery 7th ed USA: McGraw-Hill P, editors; 1999. p. 1265–76.
 12. Nivatvongs S. The biological basis of modern surgical practice. In: and others, editor. Sabiston DC, eds. Sabiston Textbook of Surgery. USA, WB-Saunders; 2008. p. 971–8.
 13. Imbembo AL, Karri A. Sabiston Textbook of Surgery. The biological basis of modern surgical practice. vol. 1997. 15th ed. Sabiston D, editor. USA, WB-Saunders; p. 1015–20.
 14. Armstrong DN, BallIntyne GH, Dudely H, Karter D, Russell RC, Pitt HA. Colonic surgery for acute condition: volvulus of the colon. 3rd ed. London, Chapman-Hall; 1996. p. 750–65.
 15. Catalano O. Computed tomographic appearance of sigmoid volvulus. *Abdominal Imaging*. 1996;21(4):314–21.
 16. Charles BF, Jaffe BM. Colon, sigmoid volvulus. In: Schwartz's Principles of Surgery. New York, McGraw-Hill; 2015. p. 1219–21.
 17. Osime U. Cite this article as: Surriah MH, Bakkour AM, Hussain NAA. Risk factors and surgical management of sigmoid volvulus among patients attending AlKarama teaching hospital of Iraq. *J Royal Coll Surg Edinburgh*. 1980;25(1):32–9.
 18. Sule AZ, Misauno M, Opaluwa AS, Ojo E, Obekpa PO. One stage procedure in the management of acute sigmoid volvulus without colonic lavage. *Surgeon*. 2007;5(5):268–70.
 19. Gupta SS, Singh O, Paramhans D, Mathur RK. Tube sigmoidostomy: a valuable alternative to sigmoidopexy for sigmoid volvulus. *J Visceral Surg*. 2011;148(2):129–62.
 20. Madiba TE, Thomson SR. The management of sigmoid volvulus. *J Royal Coll Surg Edinburgh*. 2000;45(2):74–80.
 21. Friedman JD, Odland MD, Bubrick MP. Experience with colonic volvulus. *Dis Colon Rectum*. 1989;32(5):409–25.
 22. Mokoena TR, Madiba TE. Sigmoid volvulus among Africans in Durban. *Tropical Geograph Med*. 1995;47(5):216–23.
 23. Baker DM, Wardrop PJ, Burrell H, Hardcastle JD. The management of acute sigmoid volvulus in Nottingham. *J Royal Coll Surg Edinburgh*. 1994;39(5):304–10.
 24. Bagarani M, Conde AS, Longo R, Italiano A, Terenzi A, Venuto G. Sigmoid volvulus in West Africa: a prospective study on surgical treatments. *Dis Colon Rectum*. 1993;36(2):186–90.

Author biography

Atul Kumar Khare, Senior Resident  <https://orcid.org/0000-0002-8869-5614>

Dhananjay Majhi, Senior Resident

Kuldip Pratap Patel, Assistant Professor

Cite this article: Khare AK, Majhi D, Patel KP. To identify the risk factors of sigmoid volvulus in cenral India tribal area population. *IP J Surg Allied Sci* 2023;5(1):9-13.