



Case Report

Analysis of two cases of small bowel diverticulum misdiagnosis and its comorbidities: A report of two cases

Sakarie Mustafe Hidig^{1,2,*}

¹The Fourth Affiliated Hospital, Zhejiang University School of Medicine, Yiwu, Zhejiang Province, People's Republic of China

²Dept. of General Surgery, Affiliated Hospital of Xuzhou Medical University, Xuzhou, Jiangsu, People's Republic of China



ARTICLE INFO

Article history:

Received 25-05-2023

Accepted 04-07-2023

Available online 03-08-2023

Keywords:

Aortic balloon reverse balloon (IABP)

Continuous renal replacement Therapy (CRRT)

Hemicolectomy

ABSTRACT

Background : To discuss and analyze the diagnosis and treatment methods of small bowel diverticulum to improve the level of diagnosis and treatment.

Materials and Methods: The clinical data of two patients with small bowel diverticulum found by intraoperative exploration in our hospital were analyzed, and the preoperative and postoperative diagnoses were compared, as well as the causes and treatment methods of misdiagnosis.

Results: The two patients could not be clearly diagnosed before surgery, but they were clearly diagnosed during surgical exploration, and they were discharged after surgical treatment.

Conclusion: Small intestinal diverticulum has no specific clinical manifestations; preoperatively, it is not easy to diagnose and is often diagnosed in autopsies or other operations. Patients with acute abdomen and gastrointestinal bleeding, such as small intestinal bleeding and acute appendicitis, should be vigilant for small bowel diverticula to avoid delaying the condition and causing serious consequences.

This is an Open Access (OA) journal, and articles are distributed under the terms of the [Creative Commons Attribution-NonCommercial-ShareAlike 4.0 License](https://creativecommons.org/licenses/by-nc-sa/4.0/), which allows others to remix, tweak, and build upon the work non-commercially, as long as appropriate credit is given and the new creations are licensed under the identical terms.

For reprints contact: reprint@ipinnovative.com

1. Introduction

Small intestinal diverticulum preoperative diagnosis is more challenging, and the preoperative diagnosis rate is low. It is typically diagnosed intraoperatively, and the clinical manifestations are not specific. Additionally, no one auxiliary examination can provide a precise diagnosis due to the small intestine's distinct structural features. Additionally, compared to upper and lower gastrointestinal illnesses, traditional gastrointestinal endoscopy can clearly diagnose a lesion since it is located at a deep location in the small intestine. The following reports two cases of small bowel diverticulum patients' diagnosis and treatment process: It is hoped to increase the vigilance of clinicians and improve the rate of preoperative diagnosis of small bowel diverticular disease.

* Corresponding author.

E-mail address: hidig2015@icloud.com (S. M. Hidig).

2. Clinica Data

2.1. Case 1

Recurrent small bowel bleeding caused by multiple telangiectasias of the ileum misdiagnosed as a small bowel diverticulum.

A 29-year old patient was admitted to our hospital on February 25, 2022, with intermittent blood in the stool for 5 days". The patient had bloody stool without apparent = cause five days prior; the stool was black with bright red blood on the surface. He also experienced dizziness and palpitations. The local hospital improved his blood, raising his hemoglobin level to 96g/L. He was then transferred to a higher-level hospital for further examination. Blood examination revealed a hemoglobin level of 36 g/L, hemostasis, and the patient was moved to the intensive care unit for additional treatment. Blood in the stool symptoms

persisted, however, and we continued treatment in the rescue room at which point the patient's hemoglobin level rose to 41.0 g/L. Emergency colonoscopy and gastroscopy both point to chronic non-atrophic gastritis and minor intestinal hemorrhage, respectively. "Gastrointestinal bleeding, small intestinal bleeding, severe anemia, and urgent surgical treatment" was the early diagnosis. During intraoperative exploration, it was discovered that the upper ileum is approximately 50 cm from the ileocecal intestinal wall and has a 4x4 cm diameter diverticulum. Additionally, there was ileal intestinal dilation, intestinal wall edema, diameter widening, incision of diverticulum tissue, diverticulum surface hyperemic edema, intermittent bleeding, partial ileal resection, and lateral ileal anastomosis. Upon postoperative inspection, the focal intestinal mucosa was found to have superficially eroded, as well as interstitial edema under the mucous membrane, small vessel hyperplasia, dilated hyperemia, and congestion.[Figure 1 a & b] After surgery, symptomatic supportive therapies such as anti-infection, fluid replacement, acid suppression, electrolyte and albumin supplements, hemostasis, blood transfusion, intravenous nutrition, and other symptomatic therapies were administered. On the third day following surgery, the patient experienced sudden dyspnea, a rapid heartbeat, breathing difficulties, orthopnea, and irritability after using the restroom. Blood oxygen saturation dropped to 60%, requiring endotracheal intubation and transfer to the intensive care unit for intensive treatment. These symptoms were caused by circulatory instability (BP 60/40 mmHg), brownish-red urine, an aortic balloon reverse balloon (IABP), and CRRT treatment. The blood routine showed 89 g/L. On the 12th day following surgery, blood in the stool recurred four more times in the general ward, but the situation was better than previously. The hemoglobin steadily declined to 43.00 g/L, and the blood pressure plummeted to 80/50 g/L when active bleeding in the digestive tract was taken into account. Because of this, immediate surgical care and intraoperative exploration were required. Colon inflation was obvious; the lumen revealed dark red intestinal contents, prompting the need for a gastroenterology consultant. A colonoscopy incision from the middle ileum tube wall and an inserted colonoscopy were done concurrently with the surgical procedure. The ileocecal portion was clearly visible, as were the ascending colon and transverse colon. Ileal mucosal hyperemia, scattered punctate mucosal tortuosis, and mucosal ecchymosis were also discernible. The ascending and transverse colons, as well as the ileocecal section, were all plainly visible, and there were little ulcers with a diameter of approximately 0.5 cm in the mucosal ecchymosis. Intraoperative colonoscopy suggests multiple capillary malformations and bleeding in the ileum, partial ileal right hemicolectomy, and left transverse lateral anastomosis of the ileum. After surgery, the hemoglobin was

checked again and found to be 76g/L. The condition had improved, the stool had progressively turned from black to yellow, and the patient had been released. Hemoglobin was 96 g/L after a month of monitoring, and there was no blood in the stools.

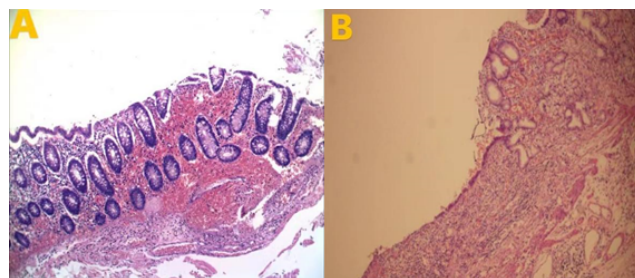


Fig. 1: A: shows first postoperative pathological results B: shows the Second postoperative pathological examination results

2.2. Case 2

2.2.1. Small bowel diverticulum perforation with acute appendicitis

A 22-year-old male was admitted to the hospital on February 13, 2023. More than a year of complaining about abdominal pain that has gotten worse in the last week. The patient was admitted to the hospital with intermittent epigastric and periumbilical pain and discomfort that gradually spread to the right lower abdomen, gradually worsened persistent colic, and radiating lower back pain that only slightly improved when he leaned forward, sat, or lay on his side after bending the knee. accompanied by intermittent nausea and vomiting; his body temperature rose to 40 °C. Once in the hospital, the patient was given antibiotic treatment. Treatment was ineffective; a year later, the aforementioned symptoms have returned and progressively worsened right lower limb straightening issues. The patient first experienced symptoms of stomach pain seven days prior, but this time they were worse than before and were accompanied by a 39 °C fever. He was admitted to our hospital for further care since the difficulties in straightening the right lower limb were worse than they had been. His "acute purulent appendicitis" led to his hospitalisation. In the right lower abdomen, there was soreness and abdominal muscular tension; there was no abdominal muscle tension; the right lower extremities were difficult to straighten; the bowel sounds were normal; and there was tenderness in the lower back.

3. Treatments and Outcomes

Test results showed the neutrophil percentage was 77.9x10⁹/L and the white blood cells were 9.6x10⁹/L. An ultrasound of the appendix revealed several inflammatory reactive hyperplasias of the peripheral mesangial lymph

nodes, acute inflammatory alterations in the ileocecal area and appendix, and the development of peripheral abscesses. Abdominopelvic CT reveals abnormal changes in the ileocecal region, taking into account infectious lesions and the development of the psoas major muscle; a right iliopsoas abscess; numerous nearby enlarged lymph nodes; a small amount of fluid in the pelvis; we attempted to drain the psoas abscess using an ultrasound-guided puncture but were unable to extract pus; and the decision was made that the patient should undergo surgical treatment.[Figure 3 A] Intraoperative findings included a small intestinal diverticulum and perforation, subsequent appendicitis, an intraoperative psoas muscle puncture without suction, concurrent partial resection of the small bowel and appendectomy, and no postoperative fever.[Figure 2] In addition to the right lower leg being straightened, improved, and discharged, symptoms of abdominal pain were also improved. The right psoas muscle and iliopsoas muscle were swollen, the density was mixed, and gas accumulated, considering the possibility of infection, and the swollen psoas muscle part of the level enveloping the inferior vena cava; pneum of the subcutaneous soft tissue of the rigour; and the patient returned to our hospital after one month of discharge with intermittent fever and an inability to straighten the right lower limb. A perfect sacroiliac joint MRI suggests right psoas muscle, iliopsoas muscle swelling, and abnormal sign.[Figure 3 B]

3.1. Follow-up and outcomes

After admission, there was still intermittent fever, body temperature up to 39 °C, antibiotic anti-infection and rehabilitation physiotherapy, right lower limb difficulties were better than before, but intermittent fever persisted. The iliopsoas intramuscular abscess and the likelihood of infections were taken into account above, with the interventional department's assistance and CT guidance for psoas puncture pathology. The findings revealed a small level of neutrophil infiltration and striated tendon fibrosis in addition to rhabdomyolysis. After receiving therapy with TCM acupuncture, muscle strengthening exercises, and neuromuscular electrical stimulation, the patient's condition improved, he was discharged, and the symptoms of his inability to straighten his right lower leg were relieved. There was also no fever.

4. Discussion

Small intestinal diverticulum refers to the local submucosa of the small intestinal mucosa caused by various etiologies through the muscular layer defect formed by the cyst-like bulge, with an incidence of 1%-3%, mostly occurring in the root of the small intestine within 100cm from the ileocecal part. Due to the increase in pressure in the intestinal cavity and the weakness of the localized intestinal wall, the cyst

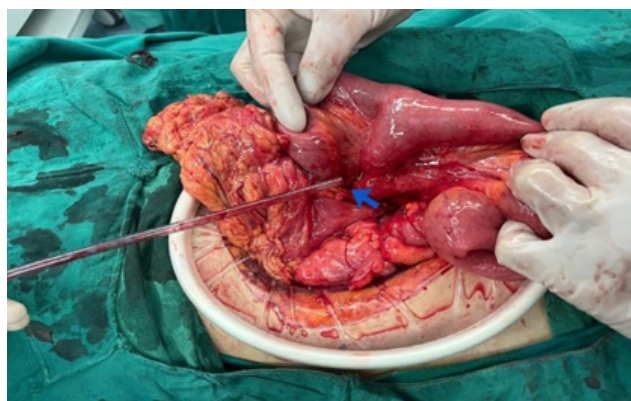

Fig. 2: Intraoperative photograph showing Ileal diverticulum

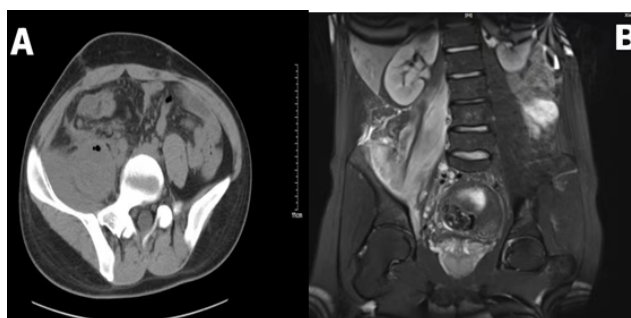


Fig. 3: A: Abdominal and pelvic CT: Shows The right psoas and iliopsoas muscles are swollen and densely mixed, and gas accumulates. The swollen psoas muscle is partially encompassed by the inferior vena cava. B: MRI of sacroiliac joint: swelling of the right psoas muscle and iliopsoas muscle with abnormal signals in them, and the formation of abscess in the psoas muscle and iliopsoas muscle.

wall may contain various layers of the small intestinal wall¹ or only mucosa and submucosa. The clinical manifestations are mainly abdominal pain, abdominal distension, nausea, melena, etc. The diverticular cystic cavity and intestinal lumen are connected, and diverticular emptying delay, food retention, chronic inflammation, and secretion of ectopic mucosa are related, which are not significantly different from other digestive system diseases. Preoperative diagnosis is difficult, often resulting in delayed diagnosis and misdiagnosis.² According to the pathogenesis, it is divided into true diverticulum (Merkel's diverticulum) and pseudo diverticulum (incidence in duodenal diverticulum autopsy: 10-20%, jejunoileal diverticulum incidence: 0.1% to 0.5%). True diverticula tend to occur in children and adolescents; pseudodiverticula tend to occur in older people; most patients are clinically asymptomatic; symptoms are often secondary to and masked by complications, often diagnosed at autopsy or other surgery; complications include gastrointestinal bleeding, intestinal obstruction, blind loop syndrome, and perforation due to diverticulitis,

with perforation being the rarest and most dangerous.^{3,4} The pathological basis of these complications lies in the histological features of the diverticulum and the type of tissue of the diverticulum mucosa, the nature of the contents of the diverticulum, and the anatomical location of specific vegetations communicating with the intestinal lumen of the small intestine. Preoperative diagnosis of small intestinal diverticulum is more difficult; the preoperative diagnosis rate is low, and it is mostly diagnosed during surgery. At present, the auxiliary diagnostic methods for small intestinal diverticula include small intestinal barium double angiography, small intestinal endoscopy, capsule endoscopy, CT examination, etc. Barium double contrast of the small intestine is an effective means to detect small intestinal diseases, with a diagnostic rate of 75%-85%. The imaging manifestations are sac-like niches on one side of the intestinal wall, and the intestinal mucosa continues to be intact. Local small bowel volvulus occlusion should be viewed in an upright or recumbent position, pressurized, or periodically reviewed to reduce missed misdiagnosis. Contrast-enhanced abdominal CT can show the location of the diverticulum and surrounding tissues of the small intestine and can be the test of choice for complications of the diverticulum of the small intestine.⁵ but neither test can directly observe the intestinal mucosa or take a biopsy, and CT has high diagnostic specificity only if the diverticulum is complicated by small bowel obstruction. Enteroscopy or capsule endoscopy can directly observe the location, size, and shape of the diverticulum; capsule endoscopy is greatly affected by intestinal peristalsis when the diverticulum opening is small or deep, making it difficult to observe; enteroscopy can observe the entire small intestine and take a biopsy; but enteroscopy and capsule endoscopy are prone to missed diagnoses due to poor bowel preparation, are expensive, and are difficult to popularize clinically. Small bowel diverticulum Preoperative diagnosis is difficult, and appendicitis at the same time is often difficult to distinguish and easy to miss. In the second patient in this case, the preoperative diagnosis is peri-appendiceal abscess combined with psoas abscess. Laparoscopic exploration can show mild appendix edema and no peri-appendiceal abscess, so turn to open the abdomen to find the ileal T-type diverticulum. In this case, if patient intraoperative observation results are inconsistent with the preoperative diagnosis, it is wise to continue exploring the main lesion when ileal diverticulitis and perforation occur, clarify the diagnosis, and avoid misdiagnosis. The diverticulum of the small intestine has no mesangium and is not fixed, which makes it easy to misdiagnose it as another acute abdomen, such as acute appendicitis, which is regarded as the main lesion and misses the real lesion, diverticulum perforation. Therefore, when appendectomy finds that appendix inflammation does not match the signs, the abdominal cavity, intestinal tube, stomach, and other

organs should be routinely explored to find hidden lesions. The first patient had a predominantly hematochezic stool due to his acute condition, and the entire small intestine was not completely examined by the previous endoscopy. Gastrointestinal endoscopy only suggests: small intestinal bleeding is possible, and failed to take biopsy pathological results to confirm, intraoperative visual exploration found a small intestinal diverticulum, we are satisfied with the found lesion - small intestinal diverticulum, but failed to comprehensively explore the lesions in the intestinal lumen of the small intestine, because the incidence of telangiectasia is low, mainly confirmed by endoscopic performance, coupled with small intestinal diverticulum perforation is rare, combined with telangiectasia is less common, with the help of intraoperative colonoscopy found small intestinal diverticulum combined lesion - small intestinal telangiectasia, and finally clarified the diagnosis. Small bowel diverticulum treatment includes conservative treatment (only with diverticulitis) and surgical treatment (when conservative treatment fails or is combined with bleeding, intestinal obstruction, and perforation), including diverticulectomy, intestinal segmentectomy, etc., which can effectively relieve the cause. We performed surgery on two patients and achieved good results, but we also found many deficiencies during the period, failed to find the main lesions in time, and when the small bowel diverticulum combined with other lesions, it caused difficulties in our diagnosis. We were hoping that clinicians would improve their understanding of small bowel diverticulum, improve the diagnosis rate, and avoid missed misdiagnoses.

5. Conclusion

Diverticula of the small bowel is less common, and patients are often associated with complications. In the clinical management of patients with acute abdomen and gastrointestinal bleeding, the possibility of small bowel diverticulum should be considered after excluding common causes, and when the results of intraoperative exploration do not match the preoperative diagnosis and signs, exploration should continue to find hidden lesions.

6. Patient Consent

Written informed consent for publication of the present report was obtained from the patients.

7. Data Availability

The authors declare that the data supporting the findings of this case are available within the article.

8. Authors Contribution

Dr. Sakarie Mustafe Hidig conceived and designed this case report and wrote the initial draft of the report and approved

the final version of the manuscript.

9. Funding Statement

The authors declare that there was no funding for the publication of this article.


10. Conflicts of Interest

The authors declare that there are no conflicts of interest regarding the publication of this article.

References

1. Xiaoling S, Shufang W, Chunxiu L. Misdiagnosis of small bowel diverticulum in 2 cases. *Med Theory Pract.* 2010;23(8):907.
2. Chun N, Caiquan Z, Jian L. Diagnosis and treatment of duodenal diverticulum. *J Chongqing Med Univer.* 2010;35(2):271–3.
3. Farné GM, Lauro A, Vaccari S. Spontaneous perforated duodenal diverticulum: wait or cut first? *J Dig Dis Sci.* 2021;66(9):2876–80.
4. Hadrich Z, Ameer B, Masmoudi H. Perforated jejunal diverticulitis with extensive diverticulosis: A case report. *J Clin Case Rep.* 2021;9(9):eo4877. doi:10.1002/ccr3.4877.
5. Mansour M, Abboud Y, Bilal R. Small bowel diverticula in elderly patients: A case report and review article. *BMC Surg.* 2022;101(1):1–11.

Author biography

Sakarie Mustafe Hidig, Assistant Professor  <https://orcid.org/0000-0002-4353-8199>

Cite this article: Hidig SM.

Analysis of two cases of small bowel diverticulum misdiagnosis and its comorbidities: A report of two cases. *IP J Surg Allied Sci* 2023;5(2):50-54.