



Short Communication

Role of indigenous cost-effective innovative extensor dynamic splint for post burns contracture of finger with subluxation

M Sharran¹, Ravi Kumar Chittoria^{2,*}, Bharath Prakash Reddy J²

¹Dept. of Orthopaedic Surgery, Jawaharlal Institute of Post graduate Medical Education and Research, Pondicherry, India

²Dept. of Plastic Surgery, Jawaharlal Institute of Postgraduate Medical Education and Research, Pondicherry, India



ARTICLE INFO

Article history:

Received 28-06-2023

Accepted 18-07-2023

Available online 03-08-2023

Keywords:

Stiff finger

Post burn

Contracture

ABSTRACT

Stiff finger is a common condition found among the elder population due to various causes. Arthritis being the major cause. Among the younger age group, it occur usually a sequel of trauma. It is a difficult condition to treat and follow up. Patient cooperation and strict adherence to exercise routines in paramount for success of treatment. The ideal treatment includes release of the adhesion, active physiotherapy. However, in the case of burns incidence of contractures are high. We devised our own splint for post burns contracture and found it to be useful.

This is an Open Access (OA) journal, and articles are distributed under the terms of the [Creative Commons Attribution-NonCommercial-ShareAlike 4.0 License](https://creativecommons.org/licenses/by-nc-sa/4.0/), which allows others to remix, tweak, and build upon the work non-commercially, as long as appropriate credit is given and the new creations are licensed under the identical terms.

For reprints contact: reprint@ipinnovative.com

1. Introduction

A common complaint of patients who are referred to a hand specialist is loss of mobility and motion of the fingers. Most often these complaints are gradual in onset, rather than starting abruptly. The stiffness and loss of mobility may or may not be associated with pain. Usually, patients complain of the inability to do activities they enjoy because of loss of gripping ability or fine dexterity. Important and common causes of this loss in mobility include Dupuytren's contracture, arthritis, locked trigger finger, and various injuries. Fortunately, there are treatments available for these conditions. Other important causes of finger stiffness and loss of motion include old tendon injuries, sprains, and fractures that have healed incorrectly.

Postburn contractures are a common occurrence after severe burn injuries. Postburn contractures can result in a flexion contracture, boutonniere deformity, burn syndactyly, metacarpophalangeal extension contracture, wrist contracture, or claw hand. The most common and

functionally limiting sequelae are contractures of the webspace, hand, and digits. Early motion and rehabilitative modalities are essential to prevent initial contracture formation and recontracture after surgical release.

Some commonly used types of hand splints include dorsal distal phalanx splints, hairpin splints, dynamic finger splints, ulnar gutter splints, radial gutter splints, dorsal splints with extension hoods, and thumb spica splints. It is imperative that hand injuries are splinted with proper technique. As the proper technique is followed, the versatile capabilities of the hand are preserved, nerve impingements are avoided, and the full range of motion is retained.

2. Materials and Methods

This study was conducted in a tertiary care center in the department of plastic surgery with departmental committee ethical approval. 22 years old gentle man with history of thermal burns to his left little finger at the age of 2 years, the patient took medical care at his locality. The wound healed however there was residual deformity secondary to post burns contracture. The the patient presented to Dept.of

* Corresponding author.

E-mail address: drchittoria@yahoo.com (R. K. Chittoria).

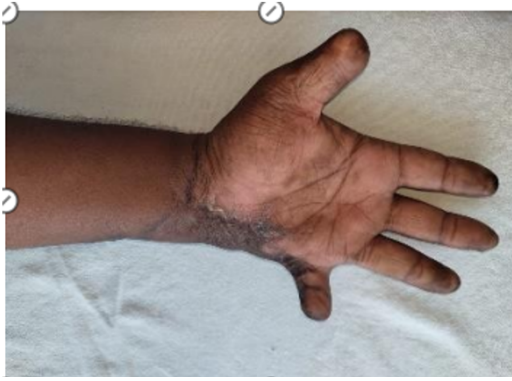

Fig. 1: Patient with flexion contracture of mcp joint of right little finger

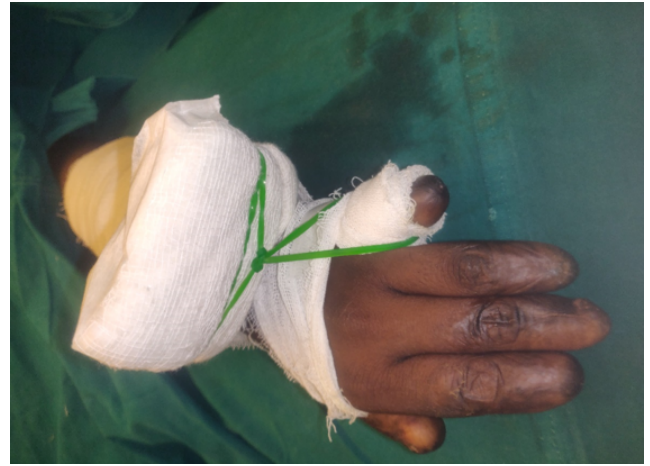

Fig. 4: Dynamic indigenous splint applied to patient

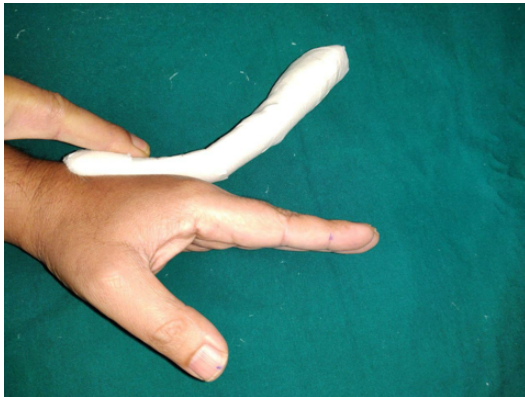


Fig. 2: Thermoplastic material modified into indigenous splint

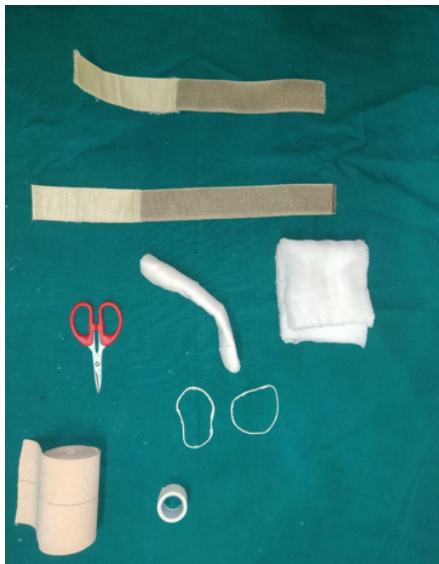


Fig. 3: Materials needed to make the dynamic splint

Plastic Surgery and was diagnosed to have contracture band with left 5 th finger subluxation (Figure 1). The contracture was released and the (MCP) metacarpo phalangeal joint was stabilized with a k wire (Figure 1). Post op the splint was provided (Figure 2). The splint was made with thermoplastic material which was given an angle of about 45 degrees, a hammock made from rubber gloves, dynaplast, Velcro straps, scissors (Figure 3). The patient was advised to continue the splint during day time and give rest during the night time. Patient was advised to be on follow up under the department of plastic surgery.¹

3. Results

The dynamic splint provided extension pull on the MCP joint of the little finger, which seemed to be useful in preventing relapse(Figure 4).

4. Discussion

"Stiff finger," defined as a finger with decreased range of motion in single or multiple joints, is found after hand injury and is classified into flexion or extension deformities. The initial response to any injury is inflammation, with pain and oedema. By 7 days leukocytes and mediators surround the injury resulting in proliferation phase, which lasts for approximately 3 weeks. Collagen get deposited initially in a disorganized way, causing adhesions. The final stage of the response to injury is remodelling of disorganized collagen. At completion of this phase, complete healing with supple skin and soft tissue, and resolution of oedema.²

The initial treatment consists of program aimed at softening and stretching scar tissue as well as maximizing passive range of motion (ROM). Exercises are often supplemented with splinting: dynamic, static-progressive, or serial static splints. All types of splints apply mechanical force to the joints at its end of motion to improve stretching

of contracted tissues. Static and static-progressive splinting apply inelastic forces to the joint to position it with maximal stretch, but needs adjusted frequently. Dynamic splints apply a preset force across the joint using springs or elastics to position the joint at maximal stretch. Both type of splinting regimen has been demonstrated to be equally effective.³ In a series of 212 stiff joints, therapy alone successfully treated 87% of PIP joint and MCP joint contractures.⁴ The groups of Flowers and Glasgow^{5–7} demonstrated that passive ROM gains are function of increasing the splint time and force applied. However, the optimal intensity and duration of therapy is ill-defined. Excessive external force can cause damage from tearing of soft tissues and ligaments or articular subluxation. Time spent splinting reach a practical maximum based on the limits of patient tolerance.^{5–7} Numerous researchers have investigated external splints for mobilizing a PIP joint flexion contracture.^{8–11} These devices, which needs to be fixed by surgery apply skeletal traction across the PIP joint by gradual extension or distraction as the device gets adjusted. These devices stretch the deeper capsuloligamentous tissues and musculotendinous units but also stretch the soft tissue and fascia, like in Dupuytren's contracture. Institutional results from these devices have shown promising improvements in PIP joint arc of motion, with a mean of 67 over long-term follow-up.¹⁰

5. Conclusion

The splint allowed to provide continuous extensor pull on the MCP joint of little finger and prevented relapse of the contracture (Figure 4). Patient was asked to be on regular follow up for further assessment

6. Authors' Contributions

All authors made contributions to the article

7. Availability of Data and Materials

Not applicable.

8. Financial Support and Sponsorship

None.

9. Conflicts of interest

None.

References

1. Young VL, Wray RC, Weeks PM, Houshian S, Jing SS, Chikkamuniyappa C, et al. The surgical management of stiff joints in the hand. *Plast Reconstr Surg.* 1978;62(6):835–76.
2. Houshian S, Jing SS, Chikkamuniyappa C, Kazemian GH, Tehrani ME. Management of posttraumatic proximal interphalangeal joint contracture. *J Hand Surg Am.* 2015;40:2081–5.
3. Michlovitz SL, Harris BA, Watkins MP. Therapy interventions for improving joint range of motion: a systematic review. *J Hand Ther.* 2004;17(2):118–49.
4. Weeks PM, Wray RC, Kuxhaus M. The results of nonoperative management of stiff joints in the hand. *Plast Reconstr Surg.* 1978;61(1):58–63.
5. Glasgow C, Wilton J, Tooth L. Optimal daily total end range time for contracture: resolution in hand splinting. *J Hand Ther.* 2003;16(3):207–25.
6. Flowers KR, Lastayo P. Effect of total end range time on improving passive range of motion. *J Hand Ther.* 1994;7(3):150–7.
7. Flowers KR. A proposed decision hierarchy for splinting the stiff joint, with an emphasis on force application parameters. *J Hand Ther.* 2002;15(2):158–62.
8. Agee JM, Goss BC. Use of skeletal extension torque in reversing Dupuytren contractures of the proximal interphalangeal joint. *J Hand Surg.* 2012;37(7):1467–74.
9. Houshian S, Chikkamuniyappa C, Schroeder H. Gradual joint distraction of post-traumatic flexion contracture of the proximal interphalangeal joint by a mini-external fixator. *J Bone Joint Surg Br.* 2007;89(2):206–15.
10. Houshian S, Jing SS, Kazemian GH. Distraction for proximal interphalangeal joint contractures: long-term results. *J Hand Surg Am.* 2013;38(10):1951–7.
11. Houshian S, Chikkamuniyappa C. Distraction correction of chronic flexion contractures of PIP joint: comparison between two distraction rates. *J Hand Surg.* 2007;32(5):651–7.

Author biography

M Sharran, Junior Resident

Ravi Kumar Chittoria, Plastic Surgery

Bharath Prakash Reddy J, Senior Resident

Cite this article: Sharran M, Chittoria RK, Bharath Prakash Reddy J. Role of indigenous cost-effective innovative extensor dynamic splint for post burns contracture of finger with subluxation. *IP J Surg Allied Sci* 2023;5(2):65–67.