

Content available at: <https://www.ipinnovative.com/open-access-journals>

IP Journal of Surgery and Allied Sciences

Journal homepage: <https://www.jsas.co.in/>

Original Research Article

A comparative study between functional and radiological outcome of short and long segment transpedicular fixation for unstable thoracolumbar vertebral fractures

Tomin P Zacarias¹, Paragjyoti Gogoi¹, Vikash Kumar Jha^{2,*},
Tulasidas Bhattacharyya¹, Kaushik Bharali³

¹Dept. of Orthopaedics, Gauhati Medical College and Hospital, Guwahati, Assam, India

²Dept. of Orthopaedics, Fakhruddin Ali Ahmed Medical College and Hospital, Barpeta, Assam, India

³Dept. of Orthopaedics, THC Hospital, Tezpur, Assam, India



ARTICLE INFO

Article history:

Received 20-08-2023

Accepted 19-09-2023

Available online 13-10-2023

Keywords:

Transpedicular fixation

Short and long segment

ASIA grade

TLICS score

ABSTRACT

Background: Management of unstable thoracolumbar fracture remains controversial between short segment and long segment pedicle screw fixation. Surgical stabilization is indicated to adequately decompress the spinal canal, maximizing neurological recovery and creating spinal stability.

Materials and Methods: A comparative study in unstable thoracolumbar fractures fixed with short and long segment transpedicular screw fixation was done and followed up for 6 months. For functional assessment Modified MACNAB criteria, Oswestry disability index and Visual analogue scale scoring system used. Neurological status, radiological kyphotic angle correction were analyzed.

Results: A total of 30 cases were included in the study of which 23 were male and 7 females. The mean age was 36.77 years. Younger individuals were more susceptible to road traffic accident. L1 was the most common vertebral level involved. Cases with a higher ASIA grade had a better improvement post operatively compared to one with a lesser ASIA grade preoperatively (P Value 0.003). Cases with lesser number of transfers had a better outcome at final followup. (P value 0.018). At all months of followup both short and long segment fixation groups have statistically significant kyphotic deformity correction, but long segment have better correction with 19.86 degrees pre-operative to 8.8 degrees at the end of 6 month of followup.

Conclusion: Short segment transpedicular fixation gives better functional outcome than long segment transpedicular fixation, but long segment transpedicular stabilization gives better radiological results in the form of kyphotic deformity correction.

This is an Open Access (OA) journal, and articles are distributed under the terms of the [Creative Commons Attribution-NonCommercial-ShareAlike 4.0 License](https://creativecommons.org/licenses/by-nc-sa/4.0/), which allows others to remix, tweak, and build upon the work non-commercially, as long as appropriate credit is given and the new creations are licensed under the identical terms.

For reprints contact: reprint@ipinnovative.com

1. Introduction

Vertebral fractures are a common component in polytrauma with 70% to 80% of these occurring at the thoracolumbar and lumbar region. Majority of these injuries occur as a result of fall from height and motor vehicle accidents.¹ The thoracolumbar junction is the anatomical and mechanical

transition zone between the relatively rigid thoracic and more flexible lumbar spine. A significant incidence of neurological deficits has been reported in patients with thoracolumbar fracture.² Unstable thoracolumbar fractures frequently require surgical correction to adequately decompress the spinal canal, maximizing neurological recovery and creating spinal stability. Involvement of all the three columns, progressive neurological deficit, significant kyphosis >30 degree and canal compromise in the presence

* Corresponding author.

E-mail address: jha.demigod@gmail.com (V. K. Jha).

of neurological deficit are accepted indications for surgical stabilization.³ A progressive neurological deficit is one of the indications for immediate surgery to treat a thoracolumbar or lumbar burst fracture.⁴ For the past 20 years there have been a dramatic increase in the operative management for vertebral fractures. The advantages of surgical treatment with pedicle screw and rod fixation systems in spine injuries are shorter hospital stay, more complete rehabilitation, fewer complications of prolonged immobilization and reduced morbidity and mortality.⁵ Transpedicular screw fixation offer superior three-column control in the absence of posterior element integrity and obviates the need for intracanal placement of hardware and produces early pain free fusion results.⁶ Stabilization with posterior pedicle screws is the most common approach today for the repair of thoracolumbar burst fractures.⁷ Long-segment pedicle screw fixation (two level above and two level below the fractured vertebral body) and short segment pedicle screw fixation (one level above and below the injured vertebra) are performed. Even though early clinical results of this surgery are usually satisfactory, a high failure rate and progressive kyphosis remain a concern. Short segment instrumentation preserve the number of motion segments and attempt to improve fusion rates, ability to obtain reduction, and maintain sagittal contour which would eventually lead to a lower incidence of residual pain.⁸ Long-segment posterior fixation offers greater stability and a more effective reduction in kyphotic deformities.⁹ However it leads to more loss of motion segments, longer operation time, more amount of bleeding and surgical muscle damage.¹⁰ Optimal surgical method is still a controversy. Hence, the aim of this study was to analyze and compare the functional outcome of thoracolumbar unstable fractures treated by short segment and long segment transpedicular instrumentation.

2. Materials and Methods

This is a prospective study of 30 patients conducted in the Department of Orthopedics, Gauhati Medical College and Hospital from January 2020 to June 2021 after obtaining institutional ethical clearance. Inclusion criteria included patients with age more than 18 years with X Ray, Computed Tomography, Magnetic Resonance Imaging showing unstable thoracolumbar fracture with or without neurological deficiency and who were motivated and willing to undergo for Surgery, physiotherapy and rehabilitation. Exclusion criteria included patients with pathological or open fracture, complete paraplegia with bowel and bladder involvement. Well informed written consent were taken from patients who fulfilled the inclusion and exclusion criteria. First assessment of a patient included history of injury, mode of injury, a thorough clinical and neurological examination, and status of the stability. Then, priorities included resuscitation of patient, and treatment of life-

threatening injuries before stabilization of the spinal injuries. The skeletal system was examined to rule out associated injuries. The patient's spine was examined for any swelling, contusion, tenderness, hematoma, gibbus or step off. Full neurological examination (sensation, motor, anal tone) was done and documented. Protection of the spinal column was given immediately. Daily neurological examination was done. Pattern & level of neurological injury were identified and noted. Anteroposterior and lateral plain X rays, CT scans, and MRI were taken to identify all injuries and to assess the severity and nature of the injury. The level and type of fractures were classified according to AO Magrel classification and TLICS score was calculated. The indications for surgical intervention were TLICS score more than four. ASIA grading was done. The patient and relatives were explained in detail about the nature and severity of injury, the possible outcomes of management and the importance of rehabilitation. Patients were randomly selected and made into two groups. Group A had 15 patients managed with short segment transpedicular screw fixation in which spanning of fractured vertebrae one above and below to the fracture was done (Figure 1). Group B included 15 patients who had been managed with long segment transpedicular screw fixation. In this group a total of 4 vertebrae were spanned, two above and two below to the fracture vertebra (Figure 2). Depending on level of vertebra and size of pedicles screws were used bilaterally. To augment torsional stability cross-links were placed cephalad and caudal to the fracture. In cases with severe neurological deficits, laminectomy was performed in order to excise the retropulsed bone fragments or disc remnants from the spinal canal. All post-op patients were administered 3rd generation Cephalosporins and Amikacin intravenously for 5 days followed by oral antibiotics for another 5 days. Immobilization done with thoracolumbar brace applied post operatively. Patient were followed up post operatively for functional outcome at 1, 3 and 6 months. At every followup neurological examination, pain relief, level of activities and bowel-bladder function were assessed. Results were evaluated clinically by Modified MCNAB criteria, Visual Analogue Scale and Oswestry Disability Index. Radiographs were taken during followup period and correction of kyphosis during the followup period were measured. All the data obtained were recorded and analyzed by SPSS software.

3. Results

A total of 30 cases were included in the study of which 10 were in the age group of 21 to 30 and 6 were in the group of 31 to 40. The mean age was 36.77 years. 23 were males and 7 were females. There were 19 cases of fall from height and 11 cases of road traffic accidents. Out of 7 female cases, 5 were road traffic accidents and 2 fall from height which is statistically significant (P Value 0.0293). Among 23 males,

Table 1: Comparison between preoperative and final followup ASIA score

Preop Asia	Final Asia Score					Total	p value
	B	C	D	E			
B	0	1	0	0		1	0.003
C	0	1	8	2		11	
D	0	0	3	14		17	
E	0	0	0	1		1	
Total	0	2	11	17		30	

Table 2: Comparison between number of transfers till transpedicular fixation and final ASIA score

Final Asia	N	Mean No. of Transfers	Std. Deviation	Std. Error	Minimum	Maximum	p-value
C	2	9.00	1.41	1.00	8	10	0.018
D	11	6.36	0.50	0.15	6	7	
E	17	5.82	1.19	0.29	5	8	
Total	30	6.23	1.25	0.23	5	10	

N Frequency

Table 3: Comparison of Kyphotic Deformation (in degrees) between different time interval in each study group.

		N	Mean	SD	Minimum	Maximum	Median	U statistics	p value
Pre Op Kyphotic Deformity	Short	15	17.8 667	5.01 237	11	26	18(12-22)	91.5	0.3 82
	Long	15	19.8 667	5.33 006	13	30	17(16-24)		
Month Kyphotic Deformity	Short	15	14.3 333	3.65 8	9	20	14(10-17)	70	0.074
	Long	15	11.9 333	2.54 858	9	18	12(10-13)		
Month Kyphotic Deformity	Short	15	12.6 667	3.10 913	8	18	12 (10-15)	50.5	0.009
	Long	15	9.93 33	1.98 086	8	16	10 (9-10)		
Month Kyphotic Deformity	Short	15	11.6 667	3.24 404	7	17	11 (9- 15)	54	0.013
	Long	15	8.8	1.47 358	6	12	8(8-10)		

N Frequency

17 were fall from height and 6 road traffic accidents. 54.5 % cases of RTA belongs to age group of 20 -30 years. 68.4 % of cases of fall from height belong to age group of 30 - 50 years. In our study we observed 11 cases with fracture at L1 level followed by 7 cases at T12 level, with sum total of 60% of fractures at T12 - L1 junction. Among 7 female cases, 6 (85.7%) had L1 level fracture (P<0.001). 12 cases (52.1%) among males had fractures at T12 - L1 junction. Majority (45.5 %) of L1 fractures were among the age group of 41 - 50 years and 85.8 % cases of T12 fractures among age group >30 years. The most common type of fracture observed in the study was AO type A-3 fracture with 15 cases, followed by 14 cases of AO type A-4 fracture. 17 cases were Grade D and 11 cases Grade C of ASIA impairment scale. Cases with a higher ASIA grade had a better improvement post operatively compared to one with a lesser ASIA grade preoperatively (P Value = 0.003). Table 1 shows comparison between preoperative and final followup ASIA score. Cases with lesser number

of transfers had a better outcome at final followup based on ASIA scale. (P value = 0.018). Table 2 shows comparison between number of transfers till transpedicular fixation and final ASIA score. 16 cases were TLICS type 5 and 14 cases with type 6. Based on Modified MCNAB criteria majority have good result at 1,3 and 6 month of follow-up. At end of 1 month, short segment group had 53.3% good results and long segment group had 46.7 % good results. At end of 3 month short group has 60 % good results and long group has 46.7 % good results. At end of 6 month short group has 60 % good results and long group has 53.3 % excellent results. Majority of post- operative patient of both group falls under minimal disability score. The comparison of MCNAB criteria between study groups has been shown Figure 3. Mean ODI score in short segment were 8.87 and 10.60 in long segment fixation at 1 month. Both groups showed a mean ODI score of 6.53 at 6 months. Long segment fixation group have statistically significant p-value < 0.001. Mean score at 1 month and 3 month were 1.67 and 1.47

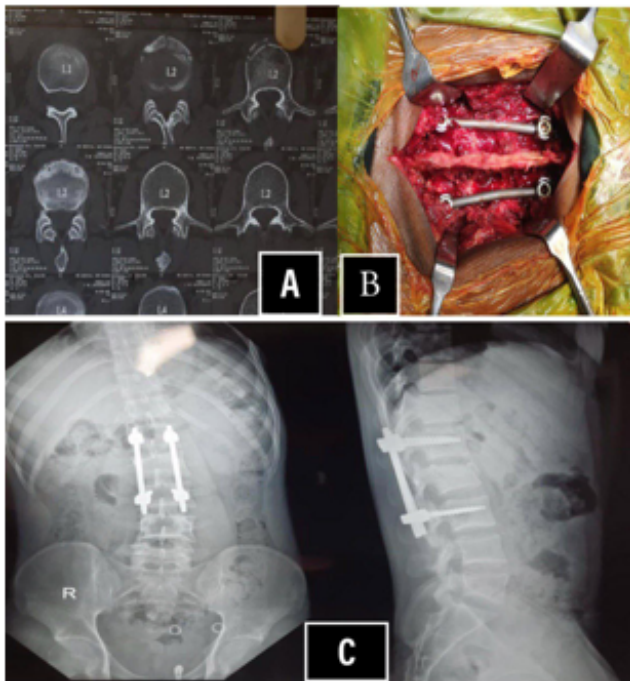


Fig. 1: Illustration in A) shows preoperative xray of 22 year old male patient with L2 burst fracture and that in B) shows intraoperative image and C) shows post operative xray after short segment transpedicular fixation.

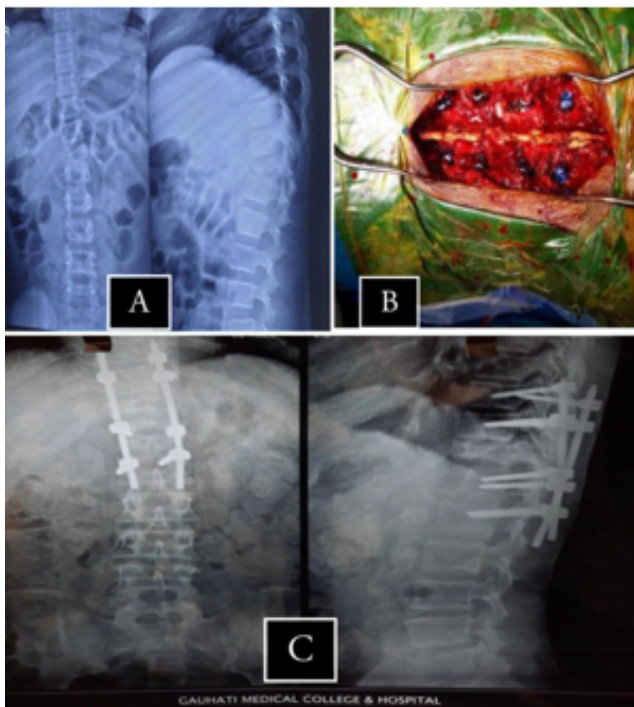


Fig. 2: Illustration in A) shows preoperative xray of 45 year old male patient with T11 burst fracture and that in B) shows intraoperative image and C) shows post operative xray after long segment transpedicular fixation.

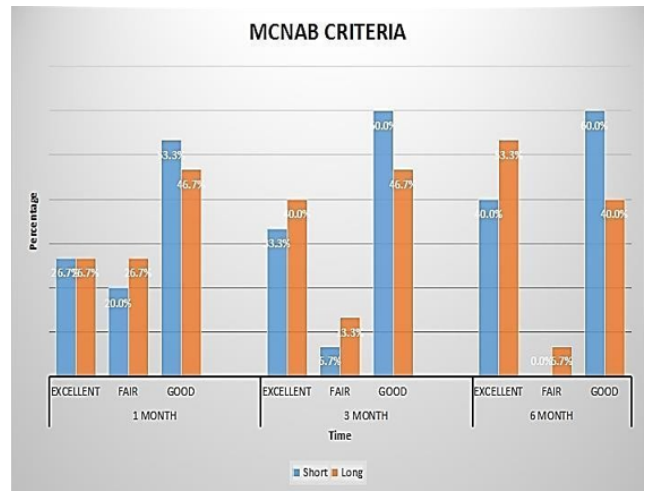


Fig. 3: Comparison of MCNAB criteria between the study groups.

in short segment fixation compared to 2.2 and 1.6 in long segment. There were similar VAS score at 6 months for both the groups. There was a significant difference ($p < 0.001$) in both groups between. At all months of follow-up both short and long segment fixation groups have statistically significant kyphotic deformity correction, but long segment have better correction with 19.86 degrees pre-operative to 8.8 degrees at the end of 6 month of follow-up. Table 3 shows comparison of kyphotic deformation between different time intervals in each study group. Thoracolumbar injuries were also associated with other injury. Patient who had fall from height usually had calcaneum fracture, ankle injuries, clavicle fracture, distal end radius fracture and those who met with road traffic accidents were associated with pelvis and acetabular fractures. In present study we had 1 cases i.e 6.7 % of implant failure in short segment fixation and 1 case of bed sore in long segment fixation.

4. Discussion

The thoracolumbar injuries of the spine are the most common in whole of spinal trauma. The anatomy of the thoracolumbar spine makes it highly vulnerable to high-energy trauma associated with motor-vehicle accidents and falls. The goal of treatment is to obtain pain free stable spine and maximum restoration of function. Spinal injuries are more common in younger individuals. In the study, 10 patients were in the age group of 21 to 30 and 6 were in the group of 31 to 40. The mean age calculated for the study was 36.77 years comparable to an average age of 35 ± 13 year in accordance with research conducted by Biakto KT et al.¹¹ These fractures usually occur in young male patients.¹² In the study of 30 cases, 23 were males and only 7 were females. The main cause of thoracolumbar burst fractures is due to fall from height.¹³ In our study 19 cases (63.3%) were due to fall from a height and 11

cases (36.7%) of road traffic accidents. Out of 7 female cases, 5 were road traffic accidents and 2 cases fall from height with a statistically significant p value of 0.0293. Among 23 males, 17 were fall from height and 6 road traffic accidents. Male patients were mostly employed in construction and tree climbing for livelihood compared to females. 54.5 % cases of RTA belongs to age group of 20 -30 years. Younger individuals were more susceptible to road traffic accident. 68.4 % of cases of fall from height belong to age group of 30 - 50 years. In our study 53.3% of the injuries were around L1 vertebra. L1 is the commonest site of injury due to the shift from less mobile to more mobile vertebral segments. This area represents the transition from normal thoracic kyphosis to flexible lumbar lordosis. This is in accordance with research conducted by Mustard et al.¹⁴ Mc Afee et al distinguished unstable burst from stable one based on the disruption of posterior elements. The most common type of fracture observed in the study was AO A-3 type fracture with 15 cases followed by 14 cases of AO A-4 type fracture. Hu R et al¹⁴ in their study concluded that in younger patients, who need more motion, and with Magerl Type A3.1 and A3.2 fractures without neurological deficit, short segment pedicle screw fixation achieves adequate fixation, without implant failure and correction loss. In Magerl Type A3.3 fractures without severe neurologic deficit (Frankel C, D, E), long segment pedicle screw fixation is more beneficial. 17 cases were Frenkel grade D and 11 cases Grade C of ASIA impairment scale. Cases with a higher ASIA grade preoperatively had a better improvement post operatively compared to one with a lesser ASIA grade preoperatively (P value = 0.003). Cases with lesser number of transfers till operative procedure had a better outcome at final followup based on ASIA scale (P value = 0.018). Post-operative ASIA grade improved in patients with incomplete paraplegia at six months after surgery which were comparable with most of the studies. There was no new onset or deterioration of neurological deficit. TLICS scoring system was used to select the cases. Scoring of more than 5 were considered for surgery. In our study 16 cases were TLICS type 5 and 14 cases with type 6. Clinical assessment was done using Modified Mcnab criteria, ODI scoring system and VAS scoring system. Patients in both groups achieved satisfactory clinical outcomes according to the modified Mcnab criteria. There was no significant difference between the groups (p value >0.05) at 1, 3 and 6 months of followup. This was in accordance with study conducted by Jin-Woo Hur et al.¹⁵ Mean ODI score in short segment were 8.87 and 10.60 in long segment fixation at 1 month. Both groups showed a mean ODI score of 6.53 at 6 months. There was a significant difference (p<0.005) between both groups showing superiority of the short segment compared to long segment in accordance to study by Canbeck et al, which concluded that there was a significant difference between

short segment fixation and long segment fixation regarding clinical outcome.¹⁶ The level of patient satisfaction was assessed by VAS. Mean score at 1 month and 3 month were 1.67 and 1.47 in short segment fixation compared to 2.2 and 1.6 in long segment and there is a similar VAS score at 6 months for both the groups. There was a significant difference. Patient complained of less pain in short segment rather than long segment on the first and third month after surgery. Patient who underwent long segment fixation had more pain and limitation of movements because of longer incision, more muscle dissection, retraction, more operative time and more blood loss, but at the end of 6 months period, long segment fixation did well when compared with short segment. It showed us the superiority of the short segment compared to long segment in the in contrast with Necdet S et al¹⁷ that, there are no significant difference between the short and the long segment pedicle screw fixation in VAS score. Tarek et al in their meta analysis concluded that long-term pain relief significantly improved in both treatment groups in all studies.¹⁸ For radiological assessment, kyphotic deformity correction was used. Mean kyphotic deformation before surgery was 17.86 degrees in short segment fixation and after correction 11.66 degrees. In long segment fixation mean kyphotic deformation before surgery was 19.86 degrees and after surgery 8.8 degrees. Our study showed long segment fixation have better results in term of correction of deformity. Tezeren et al reported that long segment fixation had a better outcome in correction of kyphotic deformity and local kyphosis than short segment fixation.¹⁹ However short segment fixation preserved motion segment. Patients who had fall from height usually had calcaneum fracture, ankle injuries, clavicle fracture, distal end radius fracture and those who met with road traffic accidents were associated with pelvis and acetabular fractures. In present study we had 1 cases i.e 6.7 % of implant failure in short segment fixation and 1 case of bedsore in long segment fixation. Daniux et al and Mirjanli²⁰ et al study showed results where implant failure in short segment fixation were 19% & 22.3% respectively. Alnay et al¹³ concluded that short segment posterior fixation alone led to a 9% to 54% incidence of implant failure and re-kyphosis in the long-term follow-up and 50% of the patients with implant failure had moderate-to-severe pain⁴¹. Tezeren and Kuru,¹⁹ in their study comparing short segment versus long segment fixation in thoracolumbar burst fractures, demonstrated that long segment instrumentation is an effective way to manage thoracolumbar burst fractures. Short segment pedicle instrumentation had a high rate of failure. However, long segment instrumentation prolonged the operative time and increased the amount of blood loss significantly. Kim et al^{21,22} suggested that short segment pedicle screw fixation without bone fusion following postural reduction can be an effective and safe operative technique in the management

of selected young patients with unstable burst fracture. Peters et al,²³ in their biomechanics study comparing short segment versus long segment fixation, found that long posterior fixation was the stiffest. The use of screws two above and two below has shown to not only enhance the stability but also allow effective reduction of kyphotic deformity. However, short posterior fixation alone has also shown to provide good clinical and radiological outcomes for certain fractures, particularly in the more lordotic middle and lower lumbar spine. Katonis et al²⁴ found that one-level above and one-level below the fracture in the lumbar area formed a rigid construct with no correction loss.

5. Conclusion

In the surgical management of thoracolumbar burst fractures through posterior approach, short segment transpedicular fixation gives better functional outcome than long segment transpedicular fixation, but long segment transpedicular stabilization gives better radiological results in the form of kyphotic deformity correction. Thoracolumbar fractures with a higher ASIA grade preoperatively had a better improvement post operatively, compared to one with a lower ASIA grade preoperatively. Thoracolumbar fractures with lesser number of transfers till operative procedure had a better outcome at final followup.

5.1. Ethics

This study proposal was approved by the Institutional Ethics Committee of Gauhati Medical College and Hospital, Guwahati, vide Letter No. NO.MC/190/2007/pt-II/Dec-2019/15 dated Sixteenth day of December, 2019.

6. Authors Contributions

TPZ: Conceptualization, methodology, investigation, formal analysis, writing, original draft preparation. TB, PG, VKJ: Data retrieval, writing – reviewing and editing. KB, SD: editing and supervision.

7. Source of Funding

This study did not receive any funding or grants.

8. Declaration of Competing Interest

None.


References

- Ravikanth M, Babu TV, Chandrasekaran A. Comparison between short and long segment transpedicular fixation of thoracolumbar burst fractures. *J Evid Based Med Healthc*. 2016;3(22):996–1001.
- Frankel HL, Hancock DO, Hyslop G, Melzak J, Michaelis LS, Ungar GH, et al. The value of postural reduction in the initial management of closed injuries of the spine with paraplegia and tetraplegia. *Spinal Cord*. 1969;7(3):179–92.
- Rajasekaran S, Kanna RM, Shetty AP. Management of thoracolumbar spine trauma: An overview. *Indian J Orthop*. 2015;49(1):72–82.
- Heary RF, Kumar S. Decision-making in burst fractures of the thoracolumbar and lumbar spine. *Indian J Orthop*. 2007;41(4):268–76.
- Bmm HD, Hussain PS. Management of unstable thoracolumbar spinal fractures by pedicle screws and rods fixation. *J Clin Diagn Res*. 2014;8(2):121–3.
- Yue JJ, Sossan A, Selgrath C, Deutsch LS, Wilkens K, Testaiuti M, et al. The treatment of unstable thoracic spine fractures with transpedicular screw instrumentation: a 3-year consecutive series. *Spine (Phila Pa 1976)*. 2002;27(24):2782–9.
- Mikles MR, Stchur RP, Graziano GP. Posterior instrumentation for thoracolumbar fractures. *J Am Acad Orthop Surg*. 2004;12(6):424–59.
- Panjabi MM, Oxland TR, Lin RM, McGowen TW. Thoracolumbar burst fracture. A biomechanical investigation of its multidirectional flexibility. *Spine (Phila Pa 1976)*. 1994;19(5):578–85.
- Serin E, Karakurt L, Yilmaz E, Belhan O, Varol T. Effects of two-levels, four-levels, and four-levels plus offset-hook posterior fixation techniques on protecting the surgical correction of unstable thoracolumbar vertebral fractures: a clinical study. *Eur J Orthop Surg Traumatol*. 2004;14(1):1–6.
- Saboe LA, Reid DC, Davis LA, Warren SA, Grace MG. Spine trauma and associated injuries. *J Trauma*. 1991;31(1):43–51.
- Biakto KT, Usman MA, Limoa W, Putra LT. Comparison between short segment pedicle screw fixation and long segment pedicle screw fixation for treatment of neglected single level thoracolumbar burst fracture. *Int J Surg Open*. 2020;26:145.
- Jansson K, Blomqvist P, Svedmark P, Granath F, Buskens E, Larsson M, et al. Thoracolumbar vertebral fractures in Sweden: an analysis of 13,496 patients admitted to hospital. *Eur J Epidemiol*. 2010;25(6):431–8.
- Alanay A, Acaroglu E, Yazici M, Oznur A, Surat A. Short-segment pedicle instrumentation of thoracolumbar burst fractures: does transpedicular intracorporeal grafting prevent early failure? *Spine*. 2001;26(2):213–20.
- Hu R, Mustard CA, Burns C. Epidemiology of incident spinal fracture in a complete population. *Spine*. 1996;21(4):492–501.
- Hur JW, Rhee JJ, Lee JW, Lee HK. A comparative analysis of the efficacy of short-segment pedicle screw fixation with that of long-segment pedicle screw fixation for unstable thoracolumbar spinal burst fractures. *Clin Med Res*. 2015;4(1):1–5.
- Canbek U, Karapinar L, Imerci A, Akgün U, Kumbaracı M, Incesu M. Posterior fixation of thoracolumbar burst fractures: is it possible to protect one segment in the lumbar region. *Eur J Orthop Surge Traumatol*. 2014;24(4):459–65.
- Saglam N, Dogan S, Ozcan C, Turkmen I. Comparison of four different posterior screw fixation techniques for the treatment of thoracolumbar junction fractures. *World Neurosurg*. 2019;123:773–80.
- Aly TA. Short segment versus long segment pedicle screws fixation in management of thoracolumbar burst fractures: meta-analysis. *Asian Spine J*. 2017;11(1):150–60.
- Tezeren G, Kuru I. Posterior fixation of thoracolumbar burst fracture: short-segment pedicle fixation versus long-segment instrumentation. *J Spinal Disord Tech*. 2005;18(6):485–93.
- Mirjanli. Comparison of Transpedicular fixation configurations in Burst fractures of thoracolumbar vertebra. *Turk Spine J*. 1995;6(3).
- Kim HY, Kim HS, Kim SW. Short segment screw fixation without fusion for unstable thoracolumbar and lumbar burst Fracture: a prospective study on selective consecutive patients. *J Korean Neurosurg Soc*. 2012;51(4):203–10.
- Kim GW, Jang JW, Hur H. Predictive factors for a kyphosis recurrence following short-segment pedicle screw fixation including fractured vertebral body in unstable thoracolumbar burst fractures. *J Korean Neurosurg Soc*. 2014;56(3):230–6.
- Peters T, Chinthakunta SR, Hussain M, Khalil S. Pedicle screw configuration for thoracolumbar burst fracture treatment: short versus long posterior fixation constructs with and without anterior column

- augmentation. *Asian Spine J.* 2014;8(1):35–9.
24. Katonis PG, Kontakis GM, Loupasis GA, Aligizakis AC, Christoforakis JI, Velivassakis EG. Treatment of unstable thoracolumbar and lumbar spine injuries using Cotrel-Dubousset instrumentation. *Spine (Phila Pa 1976)*. 1976;24(22):2352–9.

Author biography

Tomin P Zacarias, Senior Resident  <https://orcid.org/0000-0003-0426-150X>

Paragjyoti Gogoi, Assistant Professor  <https://orcid.org/0000-0002-3374-9339>

Vikash Kumar Jha, Senior Resident  <https://orcid.org/0000-0001-8339-4890>

Tulasidas Bhattacharyya, Professor

Kaushik Bharali, Senior Resident

Cite this article: Zacarias TP, Gogoi P, Jha VK, Bhattacharyya T, Bharali K. A comparative study between functional and radiological outcome of short and long segment transpedicular fixation for unstable thoracolumbar vertebral fractures. *IP J Surg Allied Sci* 2023;5(3):76-82.