



Original Research Article

Is bone-grafting or bone-healing adjunct always necessary for the treatment of non-union ? Our experience of treating non-union by primary osteosynthesis in chronically neglected shaft of femure fractures

Mohit J Jain ^{1*}, Vatsal J Mehta ¹, Hardik J Nayak ¹, Gaurav M Vadodaria ¹,
Malkesh D Shah ¹, Dhavalkumar J Patel ²

¹Dept. of Orthopedics, SBKS Institute, Vadodara, Gujarat, India

²Municipal Medical College, Ahmedabad, Gujarat, India



ARTICLE INFO

Article history:

Received 18-02-2024

Accepted 30-03-2024

Available online 10-04-2024

Keywords:

A.O. principles

Bone graft

Bone healing adjuvant

Femure Fracture

Long Bone

Non-union

Osteosynthesis

ABSTRACT

Introduction: Non-union of bone is a frightening consequence of fracture management. This condition usually occurs when the body's natural healing process cannot bridge the gap and restore the continuity of the bone. Non-infected non-union can be classified into two main types: Hypertrophic and Atrophic. Our research aims to determine the results after primary osteosynthesis without bone graft or adjuvant in neglected shaft femur fracture aseptic non-unions.

Materials and Methods : We performed a retrospective chart review to include consecutive series of neglected shaft of femur fracture non-unions treated by primary osteosynthesis surgery during a span of 3 years from 2020-2022. We excluded cases with partial union, identifiable systemic or external causes of non-union and those belonging to pediatric & elder age groups.

Results: We included 13 neglected cases of shaft femur fractures. Out of 13 patients, 7 (53.8%) were males. The mean age was 43 (range 23-55) years, and the mean injury presentation interval was 9 (range 4-18) months. Nine had hypertrophic, 2 had atrophic and 1 had undefinable non-union. At one year follow-up, 12 out of 13 showed completely united fractures with no functional limitation. Only one patient showed delayed union and eventually united. Discussion: Treating non-union requires a comprehensive approach tailored to the fracture personality. The original AO principles (1960) of fracture healing remain the mainstay of fracture healing. Besides the gold standard autologous bone graft, many biological agents like BMP are currently available to augment bone healing. However, most of them have failed to provide consistent and promising results when there is an absence of innate osteogenic potential.

Conclusion: In our experience, an excellent union rate can be achieved without the use of bone-grafting or bone-healing adjuvants in chronically neglected long bone fractures where no previous surgical attempt was made in absence of systemic and external risk factors for non-union.

This is an Open Access (OA) journal, and articles are distributed under the terms of the [Creative Commons Attribution-NonCommercial-ShareAlike 4.0 License](https://creativecommons.org/licenses/by-nc-sa/4.0/), which allows others to remix, tweak, and build upon the work non-commercially, as long as appropriate credit is given and the new creations are licensed under the identical terms.

For reprints contact: reprint@ipinnovative.com

1. Introduction

Non-union of bone is a frightening consequence of fracture management. In layperson's terms, the non-union of a long bone refers to the failure of bone healing following a

fracture, resulting in a persistent gap between the fractured bone ends. The FDA definition of non-union is a fracture that persists for at least nine months without signs of healing for at least three consecutive months.¹ This condition usually occurs when the body's natural healing process cannot bridge the gap and restore the continuity of the bone. Non-union can lead to pain, limited mobility, and functional

* Corresponding author.

E-mail address: Dr.mits4u@gmail.com (M. J. Jain).

impairment.

Infection is a significant contributing factor for non-union that must be ruled out in each non-union case. Infected non-union is a very challenging scenario and requires quite a different and individualized approach. In this study, we will limit our discussion to non-infected cases of non-unions only. Non-infected non-union can be classified into two main types:

1. Hypertrophic Non-union: In this type, there is excessive callus formation without bridging fracture site, indicating that the bone is actively attempting to heal, but there is a lack of sufficient stability or the presence of excessive mobility. In general, it's an issue with fixation.
2. Atrophic Non-union: A lack of callus formation indicates a minimal healing response. The bone ends appear narrow, suggesting a local or systemic fault in the bone healing process. Inadequate blood supply can also result in such types of non-union. Open fractures or excessive soft tissue dissection during primary surgery could be the culprit. In general, it's an issue with biology. Several systemic factors like smoking, tobacco use, diabetes, peripheral vascular disease, vitamin D deficiency, renal insufficiency, osteoporosis, anemia, long-term usage of bisphosphonates, NSAIDs, steroids, etc., do contribute to the biology of healing.

We do not support the term Oligotrophic non-union. It seems more like a mixture of the abovementioned terms and does not have its specific etiology. We neither agree with the claims of inadequate reduction with displaced fracture fragment as a cause for Oligotrophic non-union. Similarly, some authors do not support the atrophic non-union terms as atrophic and oligotrophic non-unions are histologically not different.² We believe that pseudo-arthritis is a sequelae of chronic mobile non-union, and it is not a type of non-union. Similarly, gap non-union should be referred to as any non-union where the amount of gap or displacement is significant enough (usually more than 3 mm) to exclude the possibility of spontaneous union.

Neglected fractures themselves are very uncommon in this modern era of medicine. Moreover, untreated chronic long-bone non-unions are further rare due to the morbidity associated with them. To our knowledge, no study in the literature evaluates the results of primary osteosynthesis without bone grafts or adjuvants in neglected chronic long-bone shaft fracture non-unions. Our research aims to determine the results after primary osteosynthesis without bone graft or adjuvant in neglected shaft of femur fracture aseptic non-unions. The femur is the longest and strongest bone in the human body and its growth potential is significant compared to other bones. Most pediatric shaft femur fracture unites with lengthening despite being immobilized in overlapped position during conservative

treatment.³ Although adult bone does not have growth potential as good as pediatric growing bone, we believe that a fair chance of union can still be given to primarily neglected fractures. We hypothesize that chronic aseptic non-union in shaft of femur for neglected fracture poses a lower union rate if the surgery does not include bone graft or bone healing augment.

2. Materials and Methods

We performed a retrospective study at a level I trauma center in India. We performed a chart review to include the tibia, femur, and humerus non-unions treated by primary osteosynthesis surgery during March 2020 - February 2022 (3 years). We included cases with at least two years of follow-up after revision surgery. We excluded the following cases. (1) septic (infected) non-union (2) non-union involving long bones other than femur (3) non-union involving region other than shaft of femur (4) borderline/questionable non-union with at least two cortices united (out of 4) in two X-ray views (AP and Lat) (5) patients with systemic (Anemia, Hypothyroidism, Vitamin D Deficiency, etc.) and external (open fractures. Tobacco, Smoking, Steroid, etc.) causes for non-union (6) Pediatric (<18 Years) and Elderly (>60 years) age groups.

Diagnosis of non-union involves a thorough medical history, physical examination, and X-rays. For inclusion purposes, we defined radiological non-union as a lack of signs of union in 3 out of 4 cortices in AP and later X-ray views. CT scans or MRIs were also used if needed to understand the non-union anatomy. These tests help to identify the absence of healing and provide a detailed view of the fracture site, bone quality, and surrounding tissues.

All the patients were treated with primary rigid osteosynthesis via ORIF (Open Reduction Internal Fixation). The margins of fracture fragments were thoroughly fashioned at 360 degrees after removing fibrous non-union or pseudoarthrosis. The medullary canal of both the fragments was opened, and all the tissues obstructing the canal were scooped out with a curette. Whenever the sclerosing callus/bone is found at the fracture end, it is either removed or left with multiple drill holes (by 2mm K-wire) after assuring some amount of vascularity. No bone grafts or augments were used during surgery. An interfragment screw was used in case of an oblique fracture pattern or in the presence of medium to large butterfly fragments. We aimed for the maximum compression at the fracture site and accepted any amount of shortening as compared to the unaffected side. In all cases, the drain was kept for 24-48 hours.

Post-operatively, full range of motion exercise started in all the patients on the next postoperative day. Weight-bearing/lifting was not allowed until 2 weeks in all patients. Sutures were removed at approximately 2 weeks in all patients. Gradual weight bearing was allowed after 3

weeks, and full weight bearing was allowed at 6 weeks after confirming a check X-ray. Further follow-ups were scheduled for 3 months, 6 months, 9 months, 12 months, 28 months and 2 years after surgery. X-rays (AP and Lateral views) were evaluated at every visit for the progress of union and stability of reduction. Oblique X-ray views were also taken whenever needed.

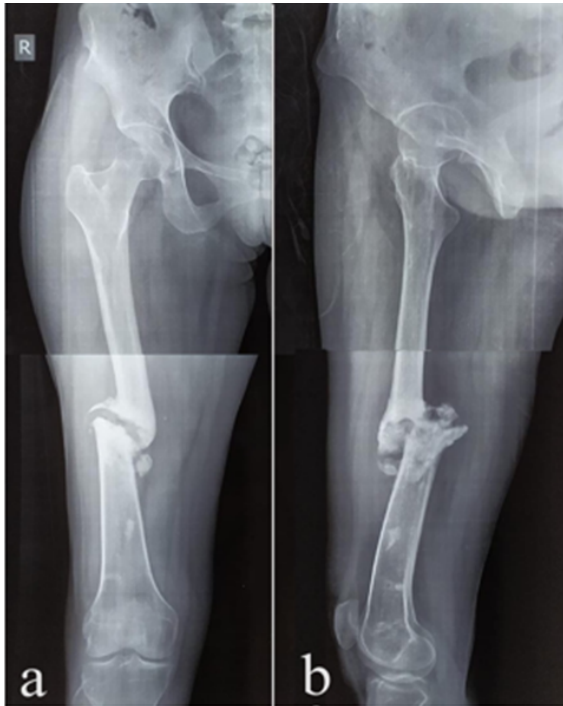

Figure 1: Case of neglected (1.5 years old injury) right shaft femur fracture in 31-year-old female patient's pre-operative X-rays (a) AP (anteroposterior) view (b) Lateral view

3. Results

We included 13 cases with shaft of femur (Figures 1, 2 and 3) fractures. Out of 13 patients, 7 (53.8%) were males and 6 (46.2%) were females. All 13 patients belong to the lower socio-economic class, and lack of insurance/affordability issues was identified as the main reason for no surgical intervention at the time of injury. Out of 13, nine had road traffic accidents, three had domestic falls, and one had assault. However, 10 out of 13 patients had a history of conservative treatment (splinting/bandaging) by quacks. The mean age of the cohort was 43 years (range 23-55 years). The mean injury presentation interval was 9 months (range 4 months -1.5 years). Out of 13 patients, nine had hypertrophic non-union, 3 had atrophic non-union, and the remaining 1 could not be categorized radiologically in either variety.

At one year follow-up, 12 out of 13 showed completely united fractures with no functional limitation. Only one

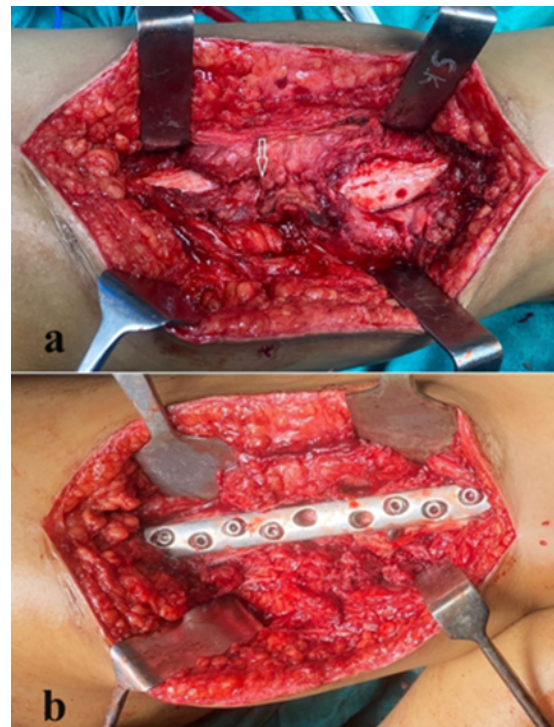


Figure 2: Intra-operative images (a) Pseudoarthrosis and fibrosis around the fracture shown by white arrow (b) Fracture fixation after freshening of margins with 4.5 mm LCDCP (Low contact dynamic compression plate) and an inter-fragmentary lag screw

patient showed delayed union and eventually united at 1 year 10 months post-operatively. The mean radiological union time was 6.5 months (range 4 months – 22 months). However, clinical union (lack of tenderness, absence of micromotion/mobility, and ability to weight bearing/successful usage of the extremity) was established in all cases prior to the radiological union. No patients developed complications of neuro-vascular injury, infection, wound healing, surrounding joint stiffness, or implant failure/loosening/impingement. Only one patient developed serous discharge from a surgical wound during the first week post-operatively. It was thoroughly debrided one week after surgery, and the culture report was negative for any organism. The wound was healed eventually without any signs of infection on follow-up. Minimum follow-up was 2 years (Maximum 4 years).

4. Discussion

Bone healing is a much more complex physiological process that includes both anabolic followed by a catabolic phase and multiple signalling.⁴ Improvement in understanding molecular and cellular events has led to the development of biological agents to augment the microenvironment for enhancing bone repair and remodeling. Various modalities to augment the inadequate bone-regeneration

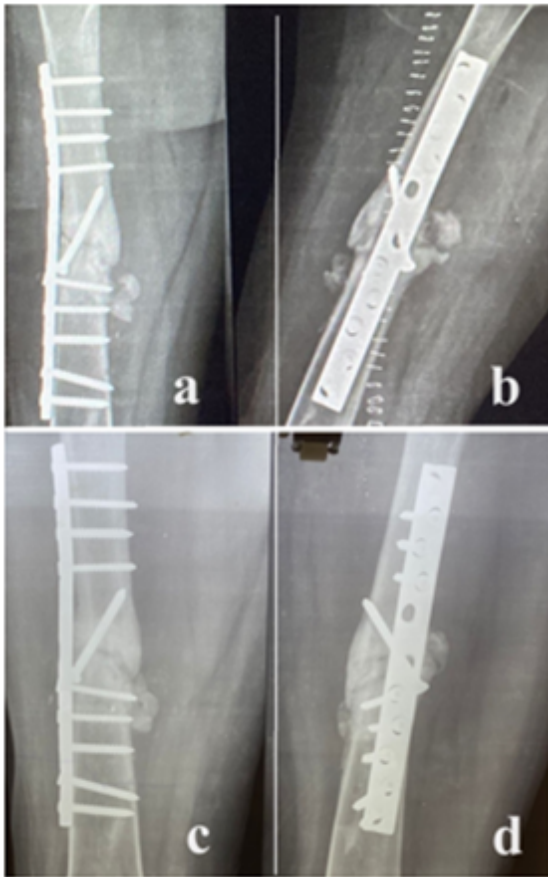

Figure 3: Post-operative X-rays (a) Fracture compressed in AP view immediately after surgery (b) Fracture compressed in Lateral view immediately after surgery (c) Fracture completely united at 8 months after surgery in AP view (d) Fracture completely united at 8 months after surgery in Lateral view

process, including autologous bone graft (mostly from the iliac crest), vascularised free fibula graft, or allograft implantation, have been used for ages. Recently, the usage of Intramedullary reaming, irrigation, and debris aspiration (RIA); osteoconductive scaffolds like G-bone (synthetic Hydroxyapatite in low crystalline form analog with another form of calcium and phosphate) and DBM (mixture of Type I collagen, noncollagenous proteins and other stimulants); growth factors such as bone morphogenetic proteins (BMP-2 and 7 is FDA approved for tibia non-union), teriparatide (parathyroid hormone) injection and stem cell therapy are gaining popularity to combat this notorious problem.

Autologous bone graft remains the gold standard, providing all the required qualities such as osteogenic, osteoinductive, and osteoconductive, and facilitating vascular in-growth. Limitations to this technique include low graft volume and donor site morbidity. Allograft has potential for risk of disease transmission and an increased susceptibility to infection. Artificial scaffolds can provide an osteoconductive construct; however, they fail to provide

an osteoinductive stimulus and frequently have poor mechanical properties. Growth factors like recombinant bone morphogenetic proteins (BMP) can provide an osteoinductive stimulus; however, they are costly and have licensing-related limitations. Various animal studies have shown the benefit of using BMP alone for bridging massive bone defects, but these effects are yet to be studied in humans.⁵ Besides, the lack of negative result studies again suggests the possibility of positive publication bias. Critics of the PPSA (Physician Payments Sunshine Act) in the United States raised notable concerns, and increasing funding from industry to orthopedic surgeons could have an adverse impact on patient care, clinical practice, and research.^{6,7} Based on the best available evidence, Garnavos C concluded that the value of Ultrasound and/or Electromagnetic stimulation, as sole therapeutic tools, is declining with time and should be considered as subsidiary methods for managing aseptic long bone non-unions.⁸

Fractures like displaced midshaft clavicular fractures and proximal humeral fractures, scaphoid waist, and thoracolumbar compression fractures have demonstrated optimal results even with non-surgical treatment.⁹ Also, problems like congenital pseudoarthrosis are still nightmares to treat due to the lack of any gold standard treatment and the requirement of multiple surgeries, including amputations.¹⁰ It suggests that external augmentation by bone graft or adjuvant has failed to provide consistent and promising results when there is an absence of innate osteogenic potential. Even though non-union is a common and difficult orthopedic problem associated with fracture treatment, literature is lacking, with studies evaluating results of isolated use of bone graft or adjuvants without revising the fixation, which is concerning. Moreover, Bhandari et al. suggested a significant lack of consensus in assessing fracture healing among orthopedic surgeons in terms of duration for non-union and delayed union.¹¹ As per current data (2023), two-year marginal cost of non-union ranged from \$33K-\$45K reoperation may added \$16K-\$34K in costs. Needless to say, infection does raise the cost further.¹²

Treating non-union requires a comprehensive approach tailored to the fracture personality. However, the original AO principles (1960) of fracture healing remain the mainstay of fracture healing¹³⁻¹⁵ i.e., (1) Restoration of anatomy, (2) Stable fracture fixation, (3) Preservation of blood supply, (4) Early mobilization of the limb and patient. We believe in these core principles, especially when we have ruled out the systemic or external causes of non-union. We have achieved a high success rate (12/13, 92.3%) in terms of timely union for challenging non-unions. We believe that compression at the fracture site ensured absolute stability, and usage of the lag screw in most cases helped to protect it. We used ORIF in each case, which has been proven superior in terms of absolute

stability. We do not believe in achieving 100% anatomical reduction by extensive periosteal dissection for these non-articular fractures. However, the removal of fibrosis and/or pseudoarthrosis and the freshening of margins is of the utmost importance. Besides, we opened the medullary canal in each case, and gentle rimming was performed as needed.

Retrospective design itself is a limitation. Lack of patient reported outcomes is another limitation. Although our study has a small sample size, it is unique, especially when finding chronically neglected femur shaft fractures, which is a rarity in the current era. All the cases were operated by a single surgeon, and this has led to a reduction of subjective bias. Our study can also act as reference for future studies in neglected long bone fractures other than shaft of femure or metaphyseal regions of long bones. Our study highlights our trust upon the natural healing potential of an adult long bone shaft, when the market of orthobiologics is growing like never before.

5. Conclusions

Extremely high union rates, in our case, are attributed to the simple and universal principles of bone healing. We recommend evaluating case-by-case bases for the use of bone-grafting or bone-healing adjuncts. In our experience, an excellent union rate can be achieved without the use of bone-grafting or bone-healing adjuvants in chronically neglected long bone fractures where no previous surgical attempt was made in absence of systemic and external risk factors for non-union.

6. Source of Funding

None.

7. Conflict of Interest

The authors declare no conflict of interests to declare with any person, company or organization whatsoever.

References


- Cunningham BP, Brazina S, Morshed S, Miclau T. Fracture healing: A review of clinical, imaging and laboratory diagnostic options. *Injury*. 2017;48(1):69–75.
- Chaudhari SK, Dhingra M, Joshi P. Is Atrophic Nonunion a Misnomer - A Hospital-based Prospective Cross-Sectional Study. *Rev Bras Ortop (Sao Paulo)*. 2022;57:1045–50.
- Wessel L, Seyfried C. Leg length inequality after childhood femoral fractures—permanent or temporary phenomenon? *Unfallchirurg*. 1996;99(4):275–82.
- Sheen JR, Mabrouk A, Garla VV. Fracture Healing Overview. In: *StatPearls*. StatPearls Publishing; 2023.
- Kamal AF, Siahaan O, Fiolin J. Various Dosages of BMP-2 for Management of Massive Bone Defect in Sprague Dawley Rat. *Arch Bone Jt Surg*. 2019;7:498–505.
- Lopez J, Ahmed R, Bae S, Hicks CW, Dafrawy E, Osgood M, et al. A New Culture of Transparency: Industry Payments to Orthopedic Surgeons. *Orthopedics*. 2016;39(6):1058–1062.
- Braithwaite J, Frane N, Partan MJ, White PB, Iturriaga C, Gruber J. Review of Industry Payments to General Orthopaedic Surgeons Reported by the Open Payments Database: 2014 to 2019. *J Am Acad Orthop Surg Glob Res Rev*. 2021;5(5):e21.
- Garnavos C. Treatment of aseptic non-union after intramedullary nailing without removal of the nail. *Injury*. 2017;48(1):76–81.
- Skou ST, Juhl CB, Hare KB, Lohmander LS, Roos EM. Surgical or non-surgical treatment of traumatic skeletal fractures in adults: Systematic review and meta-analysis of benefits and harms. *Syst Rev*. 2020;9(1):179. doi:10.1186/s13643-020-01424-4.
- Cai W, Su Y, Nan G. Novel method for the treatment of congenital pseudarthrosis of the tibia using the gastrocnemius flap: A preliminary study. *J Child Orthop*. 2022;16(3):167–73.
- Bhandari M, Guyatt GH, Swiontkowski MF, Tornetta P, Sprague S, Schemitsch EH, et al. A lack of consensus in the assessment of fracture healing among orthopaedic surgeons. *J Orthop Trauma*. 2002;16(8):562–8.
- Holy CE, Ruppenkamp JW, Vanderkarr M, Blauth M. Risk factors and healthcare costs associated with long bone fracture non-union: a retrospective US claims database analysis. *J Orthop Surg Res*. 2023;18(1):745.
- Matter P. History of the AO and its global effect on operative fracture treatment. *Clin Orthop Relat Res*. 1998;347:11–9.
- Hodgson S. AO Principles of Fracture Management. *Ann R Coll Surg Engl*. 2009;91(5):448–57.
- Mukhopadhyaya J, Jain AK. AO Principles of Fracture Management. *Indian J Orthop*. 2019;53(1):217–225.


Author biography


Mohit J Jain, Assistant Professor  <https://orcid.org/0000-0002-9193-2326>

Vatsal J Mehta, Senior Resident  <https://orcid.org/0009-0008-6475-4596>

Hardik J Nayak, Senior Resident  <https://orcid.org/0009-0008-4455-3754>

Gaurav M Vadodaria, PGY-3 Resident  <https://orcid.org/0009-0005-7725-154X>

Malkesh D Shah, Associate Professor  <https://orcid.org/0000-0003-0512-6465>

Dhavalkumar J Patel, Honorary Surgeon  <https://orcid.org/0000-0002-6202-6324>

Cite this article: Jain MJ, Mehta VJ, Nayak HJ, Vadodaria GM, Shah MD, Patel DJ. Is bone-grafting or bone-healing adjunct always necessary for the treatment of non-union ? Our experience of treating non-union by primary osteosynthesis in chronically neglected shaft of femure fractures. *IP J Surg Allied Sci* 2024;6(1):14-18.