



## Case Report

# Osteomyelitis of right coronoid process of mandible following extraction of mandibular third molar-A case report

Kavita Ramesh Wadde<sup>1</sup>, Sharanya Jillapally<sup>1\*</sup>, Varthangpuii Varte<sup>1</sup>, Hema Anukula<sup>1</sup>

<sup>1</sup>Dept. of Surgery, Government Dental College & Hospital, Mumbai, Maharashtra, India



### ARTICLE INFO

#### Article history:

Received 26-12-2023

Accepted 02-02-2024

Available online 10-04-2024

#### Keywords:

Coronoid process

Osteomyelitis

Pathological fracture

### ABSTRACT

In the maxillofacial area, osteomyelitis generally involves the mandible more commonly than the maxilla. Osteomyelitis of the mandible is often odontogenic in origin. The involvement of site other than the dentate area is very rare. We hereby report a unique case of pathological fracture of coronoid process leading to osteomyelitis following extraction of an infected third molar. It was successfully managed by pre-surgical course of antibiotics followed by resection of the coronoid process and sequestrectomy. Patient followed up for 6months no signs of recurrence.

This is an Open Access (OA) journal, and articles are distributed under the terms of the [Creative Commons Attribution-NonCommercial-ShareAlike 4.0 License](https://creativecommons.org/licenses/by-nc-sa/4.0/), which allows others to remix, tweak, and build upon the work non-commercially, as long as appropriate credit is given and the new creations are licensed under the identical terms.

For reprints contact: [reprint@ipinnovative.com](mailto:reprint@ipinnovative.com)

## 1. Introduction

Osteomyelitis is an inflammatory process of cancellous bone spreading to cortical bone, almost always involving mostly the mandible than maxilla. The mandibular angle region is an area of lowered resistance to external forces. A high percentage of mandibular fractures are located here.<sup>1</sup> Weakening the mandibular bone as a result of a decrease in its elasticity during advancing age may be a cause of the increased incidence of these fractures.<sup>2</sup> Since the most common cause is odontogenic infections, the dentate part of mandible is generally involved and rarely does it extend to the condyle and coronoid processes.<sup>3</sup> Even if involved, infections of the condyle or coronoid can either be of hematogenous origin, spread from adjacent structure or direct inoculation. Osteomyelitis is of two type; Primary chronic osteomyelitis is a non-suppurative chronic inflammation with no underlying cause. Whereas secondary osteomyelitis is usually suppurative and infective in origin developing secondary to acute symptoms,<sup>4</sup> Most commonly from odontogenic infection, complications after

tooth extraction, trauma periodontal infections, inadequate removal of necrotic bone,<sup>5</sup> According to Kim et al. 84.6% of osteomyelitis of the jaws is odontogenic in origin. The rarity of osteomyelitis of the coronoid process can be attributed it to being distant to tooth bearing areas of the jaw. Despite a distant site, osteomyelitis of condyle was most commonly odontogenic in origin with 8 out of 20 cases (40%) occurring either due to an infected 3rd molar, or infection following molar tooth extraction.<sup>6,7</sup>

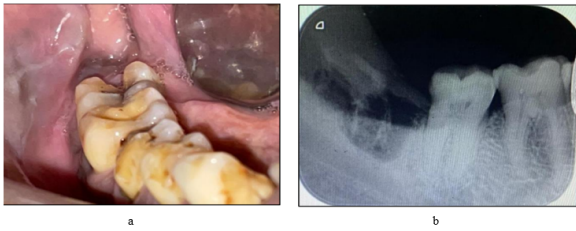
## 2. Case Presentation

A 45-year old male patient presented with a chief complaint of pain and swelling in the lower right back tooth region since 6 months. Patient presented with a swelling in the lower right back teeth region associated with occasional pain and restricted mouth opening. Patient visited a private clinic where extraction of 48 was done. After a week, he developed swelling with pain. Pain which was of intermittent in nature, dull aching, non-radiating, gradual in onset. Pain aggravated on mouth opening and mastication, not associated with relieving factors. There was no pus discharge/bleeding/mobile teeth/ fever/loss of weight etc.

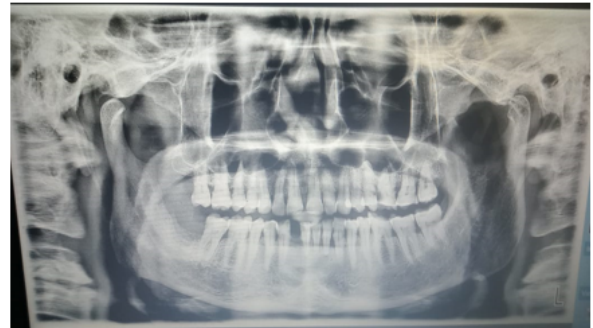\* Corresponding author.

E-mail address: [jillapallysharanya6@gmail.com](mailto:jillapallysharanya6@gmail.com) (S. Jillapally).

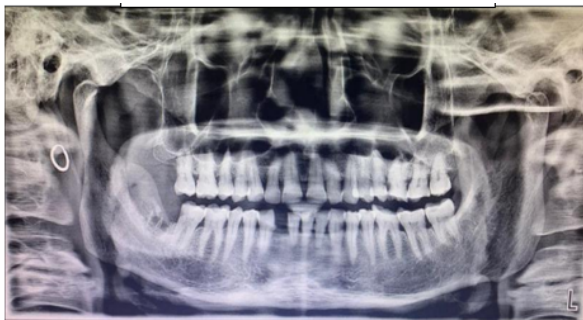Previous medical history is non-contributory.



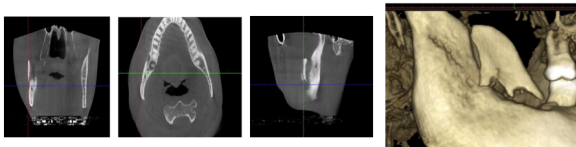
**Figure 1:** a: Pre operative clinical photograph b: Pre operative IOPA with 48 extraction socket



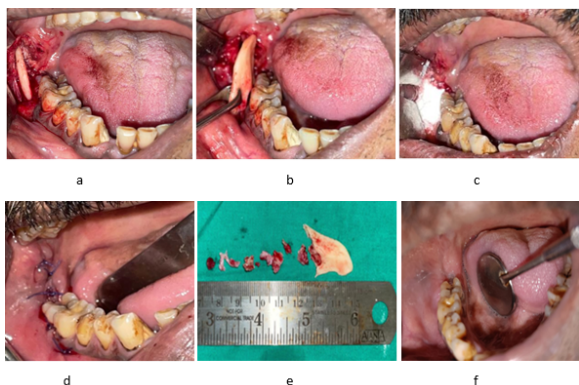
**Figure 5:** Follow up OPG after 1 year



**Figure 2:** Pre operative OPG showed fractured right coronoid process



**Figure 3:** CT Scan and 3D CT revealed fractured coronoid process



**Figure 4:** a: Vestibular incision given b: Fractured coronoid process removed c: Packed with amoxicillin powder d: Simple interrupted sutures given e: Excised specimen f: Follow up after 6 Months

On clinical examination there was a diffuse swelling present on right angle region of the mandible. Surrounding and surface skin was normal, On palpation there was mild tenderness in the near preauricular region. The swelling is associated with pain which is of intermittent in nature, dull aching, non-radiating, gradual in onset. Pain was aggravated by mouth opening and mastication, on examination of TMJ there was limited movement of TMJ nontender and no deviation on mouth opening. Submandibular lymph nodes were palpable and tender on the right side. A thorough oral examination revealed an absence for 48, with mild tenderness present posterior to 47 region. An OPG showed displaced coronoid process with loss of trabecular pattern and osteolytic changes along with extraction socket of 48. To know the extent of the lesion patient underwent a computed tomography scan (CT) revealed lytic changes with displaced right coronoid process. The patient was empirically placed on oral amoxicillin with clavulanic acid 625mg and metronidazole 400mg, Diclomol and Pan D for 5 days. Routine blood investigations were performed. All lab investigations were within normal limits. patient was subsequently operated under local anaesthesia for right coronoidectomy. Vestibular incision was taken from second molar on right side of mandible and extending till anterior border of external oblique ridge. Full thickness mucoperiosteum was reflected and the laterally displaced. Coronoid process was exposed and removed. sequestrectomy was performed around the socket of 48 thorough curettage and debridement followed by irrigation with povidone iodine was performed. Haemostasis achieved, Amoxicillin 1gm powder placed at the surgical site. Simple interrupted sutures were given along the incision. patient was advised to take oral medication for next 5 days. Histopathological examination revealed absence of osteocytes in the lacunae, absence of osteoblastic rimming. Bony trabeculae exhibited ragged margins with prominent reversal lines suggesting osteoclastic activity, marrow tissue consisted of inflammatory cell infiltrates overall findings suggested chronic osteomyelitis of coronoid process. On follow-up after 6 months and 1 year patient was free of symptoms with

improved mouth opening and completely healed extraction socket of 48. No deviation of the jaw present and occlusion was satisfactory.

### 3. Discussion

The common postoperative complications of third molar extraction are alveolar osteitis, secondary infection, bleeding, and paraesthesia. On the other hand, major complications, such as mandibular fracture, severe haemorrhage, or iatrogenic displacement of the third molar teeth leading osteomyelitis are rarely reported.<sup>8</sup> Among them, the incidence of mandibular fracture during or after a third molar extraction has been reported to be 0.0046% to 0.0049%.<sup>8</sup> The patients aged between 42 to 50 years undergo demineralization secondary to osteoporosis which weakens the skeletal system. At the same time, narrowing of the periodontal ligament increases with age. In comparison to young patients, the tooth must be freed more extensively from the surrounding bone, and the jaw is further weakened.<sup>9</sup> Older patients with a full dentition were considered to be a risk group. Moreover, most fractures associated with the extraction of teeth develop osteomyelitis usually second to fourth week from dental extraction.<sup>10</sup> In a past report, Iizuka et al. reported a case of mandibular fracture following third molar extraction with an infection at the fracture site. Therefore, it is necessary to recognize the possibility that late fracture following third molar extraction can cause osteomyelitis.<sup>11</sup> Osteomyelitis of the jaws is usually polymicrobial in nature with *Streptococcus*, *Bacteroides*, *Lactobacillus*, *Eubacterium* and *Klebsiella* being the most common offending organisms.<sup>12</sup> There has been wide variation in the age spectrum of the reported cases, varying from 14– 82 years with a mean of 40.8 years  $\pm$  21 years. No gender specificity has been found with the disease affecting. Risk factors for osteomyelitis of jaw include chronic systemic disease, alterations in the vascularity of bone and compromised host defences like diabetes mellitus, malignancy, malnutrition, acute and chronic anaemias, osteopetrosis, intravenous drug abuse or AIDS.<sup>13</sup> Secondary chronic osteomyelitis is currently considered the most frequent form of osteomyelitis with an incidence of 70% while the incidence rate of acute osteomyelitis is 17% and primary chronic osteomyelitis is 10%.<sup>14</sup> There are probably several factors responsible for the pathogenesis of the patient's osteomyelitis. The coronoid process is supplied primarily by the temporalis muscle vessels, unlike the remaining mandible, which receives its major blood supply from the inferior alveolar artery. Continued soft-tissue inflammation could have caused inflammatory exudate to pass through the nutrient or Haversian canals, and/or through the temporalis muscle, to the periosteum, causing thrombosis. Moreover, the facial swelling could have resulted in temporalis muscle compression, which could also disrupt the blood flow to the

coronoid process. A combination of these events would be enough to cause vascular collapse and associated venous stasis, and result in ischemic changes in the coronoid process that would predispose to the development of osteomyelitis.<sup>15</sup> In our case the occurrence of coronoid osteomyelitis could be followed by the removal of infected third molar.

### 4. Conclusion

To conclude, the reason for fracture of the coronoid process could be temporalis muscle pull or compromised vascularity causing the pathological fracture. The literature shows occurrence of osteomyelitis of mandible following third molar extraction the involvement of coronoid process with the disease is very rare. This report presents a case of pathological fracture of coronoid process which lead to osteomyelitis of coronoid process following extraction infected third molar with detailed explanation of surgical procedure performed.

### 5. Source of Funding

None.

### 6. Conflict of Interest

None.

### References

1. Krimmel M, Reinert S. Mandibular fracture after third molar removal. *J Oral Maxillofac Surg.* 2000;58(10):1110–2.
2. Wagner KW, Otten JE, Schoen R, Schmelzeisen R. Pathological mandibular fractures following third molar removal. *Int J Oral Maxillofac Surg.* 2005;34(7):722–8.
3. Chattopadhyay PK, Nagori SA, Menon RP, Thanneermalai B. Osteomyelitis of the Mandibular Condyle: A Report of 2 Cases With Review of the Literature. *J Oral Maxillofac Surg.* 2016;75(2):27649464.
4. Kim SG, Jang HS. Treatment of chronic osteomyelitis in Korea. *Oral Surg Oral Med Oral Pathol Oral Radiol Endod.* 2001;92:394.
5. Thoma KH. *Oral Surger.* 4th ed. St Louis, Mosby; 1983.
6. Lambade P, Lambade D, Dolas RS. Ectopic mandibular third molar leading to osteomyelitis of condyle: A case report with literature review. *Oral Maxillofac Surg.* 2013;17:127.
7. Yamamoto S, Taniike N, Yamashita D, Takenobu T. Osteomyelitis of the Mandible Caused by Late Fracture following Third Molar Extraction. *Case Rep Dent.* 2019;p. 5421706.
8. Iizuka T, Tanner S, Berthold H. Mandibular fractures following third molar extraction: A retrospective clinical and radiological study. *Int J Oral Maxillofac Surg.* 1997;26(5):338–43.
9. Wagner KW, Otten JE, Schoen R, Schmelzeisen R. Pathological mandibular fractures following third molar removal. *Int J Oral Maxillofac Surg.* 2005;34(7):722–8.
10. Ethunandan M, Shanhana D, Patel M. Iatrogenic mandibular fractures following removal of impacted third molars: an analysis of 130 cases. *Brit Dent J.* 2012;212(4):179–84.
11. Iizuka T, Tanner S, Berthold H. Mandibular fractures following third molar extraction. A retrospective clinical and radiological study. *Int J Oral and Maxillofac Surg.* 1997;26(5):338–43.
12. Coviello V, Stevens MR. Contemporary Concepts in the Treatment of Chronic Osteomyelitis. *Oral Maxillofac Surg Clin North Am.*

- 2007;19(4):523–34.
13. Koorbusch GF, Fotos P, Goll KT. Retrospective assessment of osteomyelitis. *Oral Surge Oral Med Oral Pathol.* 1992;74(2):149–54.
  14. Rajendiran R, Marimuthu M, Wahab A, Sridharan G. A Rare Case of Osteomyelitis Presenting as Cyst-Like Lesion in the Coronoid Process: A Diagnostic Challenge. *Cureus.* 2021;13:8573064.
  15. Reck SF, Fielding AF, Hess DS. Osteomyelitis of the coronoid process secondary to chronic mandibular third molar pericoronitis. *J Oral Maxillofac Surg.* 1991;49(1):89–90.

### Author biography

**Kavita Ramesh Wadde**, Head

**Sharanya Jillapally**, PG Student

**Varthangpuii Varte**, Dental Surgeon

**Hema Anukula**, Assistant Professor

**Cite this article:** Wadde KR, Jillapally S, Varte V, Anukula H. Osteomyelitis of right coronoid process of mandible following extraction of mandibular third molar-A case report. *IP J Surg Allied Sci* 2024;6(1):25-28.