

## Primary tubercular gluteal abscess: A rare presentation

Manmeet Kaur<sup>1\*</sup>, Raj Rishi Sharma<sup>2</sup>, Ranjeet Rathore<sup>3</sup>, Anil Gupta<sup>4</sup>

<sup>1,3</sup>Assistant Professor, <sup>2</sup>Professor, <sup>4</sup>Consultant, <sup>1-4</sup>Dept. of Surgery, <sup>1-4</sup>GMC, Kathua, Jammu and Kashmir, India

\*Corresponding author: Manmeet kaur

Email: drmanmeetkaur79@gmail.com

### Abstract

Tuberculosis has again emerged as public health problem with its resurgence in recent times, is with myriad and unusual presentations in extrapulmonary disease forms. TB of the soft tissue is a rare entity and occurrence of this as a primary tubercular abscess after intramuscular injections in an immune competent person is still rarer. It requires high index of suspicion and appropriate diagnostic methods. We present a case of 45 years old female with this rare presentation.

**Keywords:** Tuberculosis, Gluteal, Inoculation.

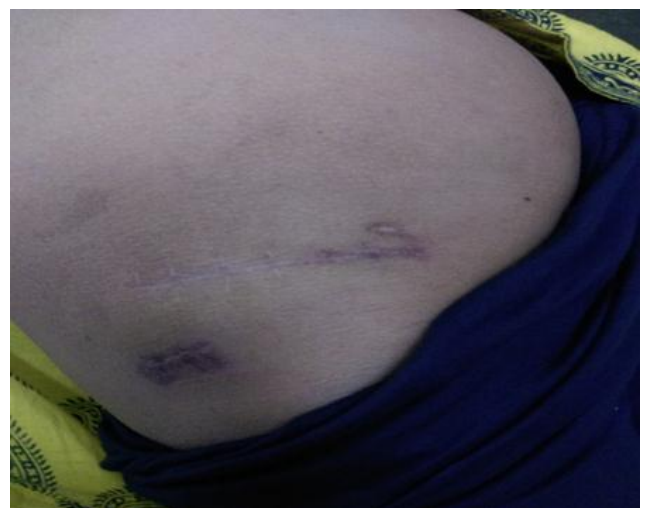### Introduction

Tuberculosis the mysterious disease is with varied presentations and has been a public health problem both in developing as well as developed countries especially in recent times, when many old diseases have reappeared tuberculosis has come to the forefront. Tubercular abscess is usually an extension from the underlying lymphnode or bone, but occurrence at the site of intramuscular injections is rare.<sup>1,2</sup> Gluteal tuberculous abscess is a well documented presentation of a caries spine and other local bony foci of tuberculosis. A primary gluteal tuberculous abscess is rarer still and though has been previously reported in literature in adults. Caries spine causing a gluteal abscess has been reported in adults and children.<sup>3</sup> Adjacent bony lesions can also at times cause gluteal abscess.<sup>4</sup> Less than half a century ago there was an epidemic of inoculation tuberculosis in children following vaccination against pertussis.<sup>5</sup> We present a case of cold abscess with a history of recent intramuscular injection therapy followed by swelling left thigh.

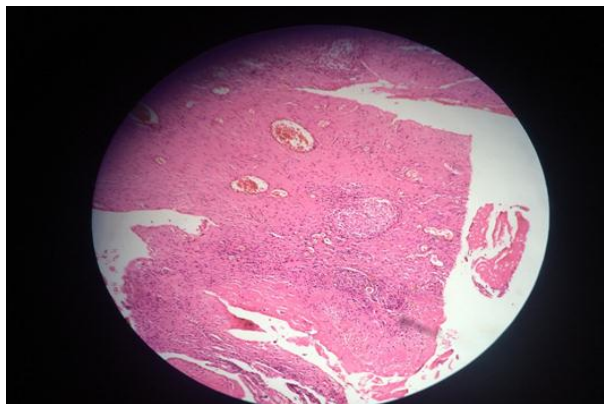
### Case study

45 years old female presented in opd with pain and swelling left thigh and buttock region laterally for one month. On examination swelling was about 8×5cms, fluctuant, slightly mobile, not fixed to skin. Skin colour and movements of the lower limbs were normal. Yellowish fluid with sediments was aspirated and swelling decreased in size. Fluid was sent for cytology which showed few histiocytes, lymphocytes and neutrophils in proteinaceous background suggestive of inflammatory swelling. Course of antibiotics and anti inflammatory given but cyst increased in size again. The patient however reported no other symptoms of cough, chills, fatigue, trauma, or any previous exposure or treatment for TB. On general physical examination, there was no evidence of poor nutrition, lymphadenopathy, or other skin lesions. Hb was 11.4gm% and TLC was 5820 /cumm She had been vaccinated in her childhood with BCG as evident with the scar in her left arm. Sputum for acid fast bacillus (AFB) was negative. X-rays of chest, spine and pelvis were normal.

An oblique incision was made and we found that a large cyst was present there and to our surprise the part of cyst was going deep into the muscles and was much bigger than expected. Cyst was of about 10 × 8 cm in size, thick walled, adherent to the gluteal muscles and contained yellowish thick fluid. Cyst was removed in total. Skin was closed primarily, along with negative pressure suction drain. Stitches were removed on the 14<sup>th</sup> day. Drain was kept till drain output became less than 15ml. The wound healed well (Fig. 1) Fluid sent for cytology on ZN staining showed occasional AFB. Histopathology showed fibrocollagenous tissue with multiple granulomas with areas of caseous necrosis. AFB not seen (Fig. 2). Patient started with antitubercular drugs. Anti-tuberculosis chemotherapy was started with rifampicin, INH, pyrazinamide and Ethambutol. The last two drugs were withdrawn after two months and first 2 drugs were continued for 4 months. At the 6-month follow-up, the patient was asymptomatic without any recurrence.



**Fig. 1: Post operative healed wound**



**Fig. 2: Histopathology picture.**

### Discussion

Tubercular abscess usually occurs by direct extension from the neighbouring joint or rarely by haematogenous or lymphatic spread from the infection in pulmonary or extrapulmonary site, though a primary focus may not be detected in every case.<sup>1,6</sup> Postinjection tubercular abscess are very rare and theoretically occur in two ways. Firstly through a primary inoculation, if the organisms are introduced by contaminated injection material or instrument, which is usually rare.<sup>6</sup> The second and common pathogenesis is seen in cases who have recently contacted primary infection and during this early stage of the disease a number of bacilli reach the blood stream, either directly from the initial focus or via regional lymph node and thoracic duct.<sup>6,7</sup> This sporadic dissemination, also termed as occult haematogenous tuberculosis, takes place for a very short time and is unlikely to continue after delayed hypersensitivity develops. During this period the main clinical manifestations is fever lasting for a few days. The bacilli are seeded at various organs and may heal completely, progress to active lesion or remain quiescent containing viable bacilli to become active again during lowered body resistance. Microhaematoma that occurs at the injection site, in patients with primary infection acts as an area of lowered resistance resulting in seedling of tubercular bacilli that get fixed at these injection sites and later progress to abscess formation if conditions are appropriate.<sup>8</sup> It is possible that high lactic acid content, absence of reticulo-endothelial cells and lymphatic tissue with very rich blood supply may help in localization of mycobacteria in the muscles.<sup>9</sup> Post injection tubercular abscess should be considered in the differential diagnosis of any chronic local abscess that forms at the injection site especially if there has been an interval of two to three weeks between injection and the development of abscess.<sup>10</sup> The distinction between a tuberculous abscess and injection abscesses caused by *Mycobacterium fortuitum* and *M. chelonae* is by a therapeutic trial of ATT to which the latter do not respond.<sup>11</sup> In a study by Patra et al.<sup>12</sup> BCG vaccination scar was found in 59.62% of cases of TB, which reflects the incapability of the vaccine to protect TB completely. However, an isolated tuberculous infection and abscess is a rare phenomenon reported rarely.<sup>13</sup> Thus, tubercular infection/abscess should

be considered in the differential diagnosis of any chronic infection/local abscess that forms especially if there has been an interval of 2–3 weeks between injury and the development of abscess.

### Conclusion

Cutaneous TB is one of the myriad of presentations of TB especially in high-risk patients. It should be considered in the differential diagnosis of any chronic and atypical skin lesions suggestive of underlying infectious etiology especially for any swelling/ sinus or cyst at an injection site presenting without any signs of inflammation, and not responding to antibiotics, a possibility of cutaneous tuberculosis should be kept in mind. This can be achieved with high index of suspicion and appropriate diagnostic methods.

**Funding:** None.

**Conflict of interest:** None.

**Ethical approval:** Yes.

### References

1. Miller FJW. Tuberculosis in Children. 1st edition. New Delhi:BI Churchill Livingstone, 1986.
2. Billimoria FJ, Bhattacharjee S. Tuberculous abscess occurring at the site of penicillin injection. *J Indian Med Assoc* 1961; 37:290-291.
3. Kumar R, Chandra A. Gluteal abscess: a manifestation of Pott's spine. *Neurol India* 2003; 51: 87-88.
4. Kim NH, Lee HM, Yoo JD, Suh JS. Sacroiliac joint tuberculosis: Classification and treatment. *Clin Orthop* 1999; 358: 215-222.
5. Oka S, State M. 13 year follow up study of an epidemic inoculation tuberculosis in children caused by vaccination against Pertussis. *Am Rev Respir Dis* 1963;88: 462.
6. Speert DP. Tuberculosis. In: Krugman S, Katz SI, Gershon AA, Wilfort CM, editors. Infectious Diseases of Children. 9<sup>th</sup> ed. Missouri: Mosby, 1992: 551-552.
7. Kovats F, Miskovits G, Hutás I. Experimental studies on the formation of tuberculous abscesses following intramuscular injections. *Orv Hetil* 1955; 9; 96: 1126-9.
8. Jones VS, Philip C. Isolated Gluteal Tuberculosis. *Indian Pediatric J* 2005; 42: 955.
9. Peter CK. Some thoughts on tuberculosis of fascia and muscle. *Lancet* 1937;57:156-159.
10. Tomar RP, Gupta A, Wilkhoo NS, Bhalla PJ. Tubercular abscess following intramuscular injections. *Armed Forces Med J India* 2007;63:374-375.
11. von Lichtenbert F. Infectious disease. In: Cotran RS, Kumar V, Robbins SL, editors. Robbins Pathologic basis of Disease. 4th ed. Philadelphia: WB Saunders: 1989. p 380
12. Patra AC, Gharami RC, Banerjee PK. A profile of cutaneous tuberculosis. *Ind J Dermatol* 2006;51(2):105-107
13. Abdelwahab IF, Kenan S, Hermann G, Klein MJ Tuberculous gluteal abscess without bone involvement. *Skeletal Radiol* 1998;27:36-39.

**How to cite this article:** Kaur M, Sharma RR, Rathore R, Gupta A, Primary tubercular gluteal abscess: A rare presentation. *J Surg Allied Sci* 2019;1(1):26-27.