

Temporomandibular joint disorders: A case series

Shaik Ali Hassan¹, Sumit Bhateja^{2,*}, Neha Aggarwal³, Geetika Arora⁴

¹Dental Surgeon, ²Reader and HOD, ³Senior Lecturer, ⁴Reader, ^{2,3}Dept. of Oral Medicine and Radiology, ⁴Dept. of Public Health Dentistry, ¹⁻³Manav Rachna Dental College Faridabad, Haryana, ⁴Inderprastha Dental College Sahibabad Uttar Pradesh, India

***Corresponding Author: Sumit Bhateja**

Email: sumit.mrdc@mrei.ac.in

Abstract

Temporomandibular disorders (TMD) is a musculoskeletal disorder that influences masticatory muscles, temporomandibular joint (TMJ), teeth, and periodontal associated structures.

The article emphasises on TMJ Disorders Case series

Keywords: TMJ Disorders.

Introduction

Temporomandibular disorders (TMD) is a musculoskeletal disorder that influences masticatory muscles, temporomandibular joint (TMJ), teeth, and periodontal associated structures.¹ Patients usually report masticatory myalgia and arthralgia, and the primary goal of the treatment is to relieve pain.² In severe cases, TMD is associated with tinnitus, ear fullness, and sometimes hearing loss.³ Etiology of TMD is related to trauma and stress and is commonly reported with occlusal factors.⁴ Distortion in maximum intercuspal position (ICP) results in transient local tooth pain, tooth migration and hence, alterations in chewing patterns, causing slight changes in postural muscle tension. ICP interference might lead to transient disruption of smooth jaw functioning, leading to jaw muscle pain and clicking occasionally.⁵

Case Report 1

A forty eight year old male patient reported to the Department of oral medicine and radiology with a chief complaint of pain with respect to both sides of face and neck for past one month. He is a daily wage labour and first experienced pain with relation to sides of face a 15days ago. The pain radiated to the sides of the temples, jaws. The pain aggravated on chewing food and was associated with frequent headache. He has no relevant medical history. Patient brushes with help of datun.

On intraoral examination it was observed he had a normal class I occlusion with a full complement of teeth. He had no restorations and no decay in any of his teeth. The patient complains of clicking on opening the temporomandibular joint (TMJ) and on palpation revealed tenderness in cheek areas. He had a normal mouth opening. He also had tenderness on palpation of the body of the mandible.

He was advised for the orthopantogram revealed no anomaly of TMJ. There was no erosion of the head of the condyle characteristic of rheumatoid arthritis.



Fig. 1: Extraoral picture of patient

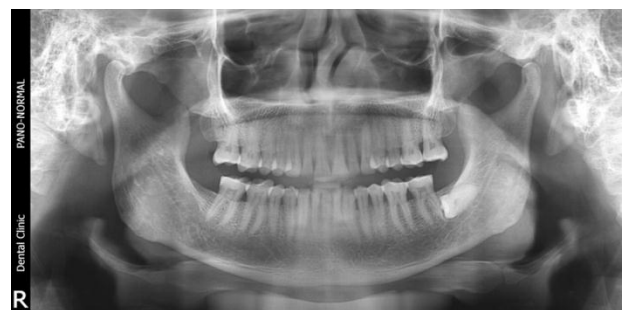

Fig. 2: Orthopantogram of patient

Case Report 2

A twenty eight year old male patient reported to the Department of oral medicine and radiology with a chief complaint of decayed tooth for past one month. He is a student. The pain radiated to the sides of the temples, jaws. The pain aggravated on chewing food and was associated with frequent headache. He has no relevant medical history. Patient brushes once daily with the help of toothpaste and toothbrush.

On intraoral examination it was observed he had a normal class I occlusion with a full complement of teeth. He had no restorations and decay in the 35 and 36 there was positive on tenderness on percussion in 35 and 36, root

stumps seen in 26. On careful examination there was clicking on opening the temporomandibular joint (TMJ) and on palpation revealed tenderness in cheek areas. He had a normal mouth opening. He was advised for the orthopantogram revealed anomaly of TMJ. There was no erosion of the head of condyle but the condyle was displaced from its usual glenoid fossa which is indicative of anterior disc displacement.



Fig. 3: Extraoral photograph of patient

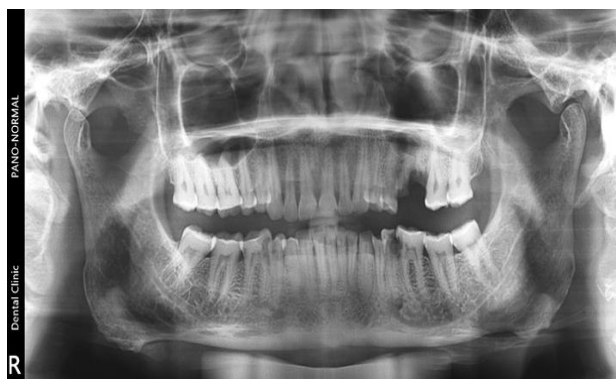

Fig. 4: Orthopantogram of patient

Case Report 3

A twenty two year old male patient reported to the Department of oral medicine and radiology with a chief complaint of pain in jaw for past one month. He is a student. The pain radiated to the sides of the temples, jaws. The pain aggravated on chewing food and was associated with frequent headache. He has no relevant medical history. Patient brushes once daily with the help of toothpaste and toothbrush.

On intraoral examination it was observed he had a normal class I occlusion with a full complement of teeth. He had no restorations and decay and no decay. On careful examination there was clicking on opening the temporomandibular joint (TMJ) and on palpation revealed tenderness in cheek areas. He had a normal mouth opening. He was advised for the orthopantogram revealed anomaly of TMJ. There was no erosion of the head of condyle but the

condyle was displaced from its usual glenoid fossa which is indicative of anterior disc displacement on left side.

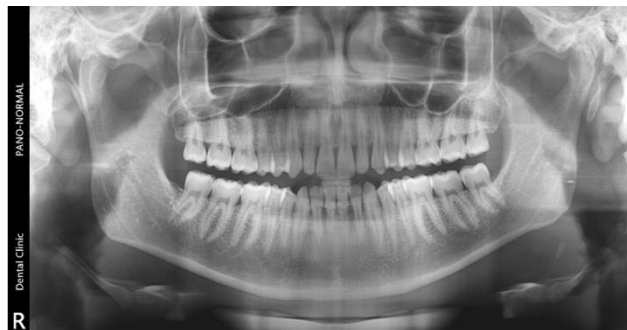


Fig. 5: Orthopantogram of patient

Case Report 4

A thirty three year old male patient reported to the Department of oral medicine and radiology with a chief complaint of pain with respect to both sides of face and neck for past five months. He is a self employed and first experienced pain with relation to sides of face a 1 month ago. The pain radiated to the sides of the temples, jaws. The pain aggravated on chewing food and was associated with frequent headache. He has no relevant medical history. Patient brushes with help of toothpaste and toothbrush.

On intraoral examination it was observed he had a normal class I occlusion with a full complement of teeth. He had restorations in 36 and 47 and no decay in any of his teeth. Patient also had missing 37. The patient complains of clicking on opening the temporomandibular joint (TMJ) and on palpation revealed tenderness in cheek areas. He had a normal mouth opening. He also had tenderness on palpation of the body of the mandible.

He was advised for the orthopantogram revealed no anomaly of TMJ. There was no erosion of the head of the condyle characteristic of myofascial pain dysfunction syndrome.

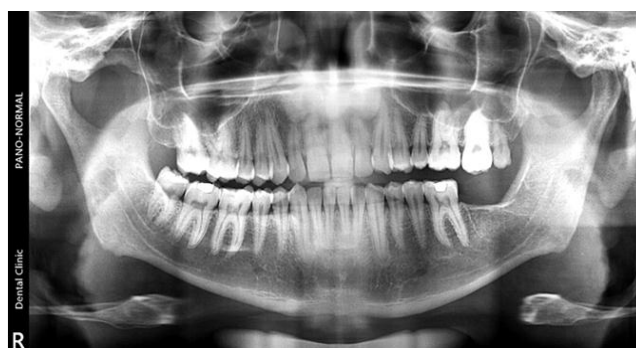

Fig 6: Orthopantogram of patient

Case Report 5

A sixty seven old female patient reported to the Department of oral medicine and radiology with a chief complaint of pain in jaws for past 1 year. The pain radiated to the sides of the temples, jaws. The pain aggravated on chewing food and was associated with frequent headache.

He has no relevant medical history. Patient brushes once daily with the help of toothpaste and toothbrush. On intraoral examination it was observed he had a normal class I occlusion with loss of teeth. He had no restorations. She had missing 46,47,36,37,24,25,17. On careful examination there was clicking on opening the temporomandibular joint (TMJ) and on palpation revealed tenderness in cheek areas. She had a normal mouth opening. He was advised for the orthopantomogram (Fig. 7) revealed anomaly of TMJ. There was no erosion of the head of condyle on right side but the condyle was displaced from its usual glenoid fossa which is indicative of anterior disc displacement.

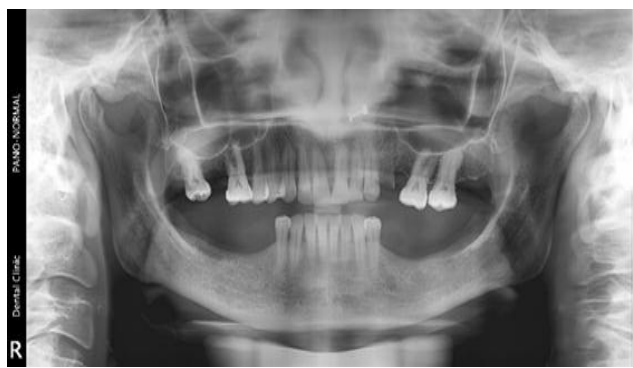

Fig. 7: Orthopantomogram of patient

Case Report 6

A twenty year old male patient reported to the Department of oral medicine and radiology with a chief complaint of pain with respect to both sides of face and neck for past nine month. He first experienced pain with relation to sides of face. The pain radiated to the sides of the temples, jaws. The pain aggravated on chewing food and was associated with frequent headache. He has no relevant medical history. Patient brushes with help of toothpaste and toothbrush. On intraoral examination it was observed he had a normal class I occlusion with a full complement of teeth. He had no restorations and no decay in any of his teeth. The patient complains of pain on opening the temporomandibular joint (TMJ) and on palpation revealed tenderness in cheek areas. He had a normal mouth opening. He also had tenderness on palpation of the body of the mandible for muscle examination. He was advised for the orthopantomogram which revealed no anomaly of TMJ. There was no erosion of the head of the condyle which is characteristic of myofascial pain dysfunction syndrome.

He was asked to take soft diet perform certain muscle relaxation exercises. He was prescribed with the muscle relaxants including flexon.

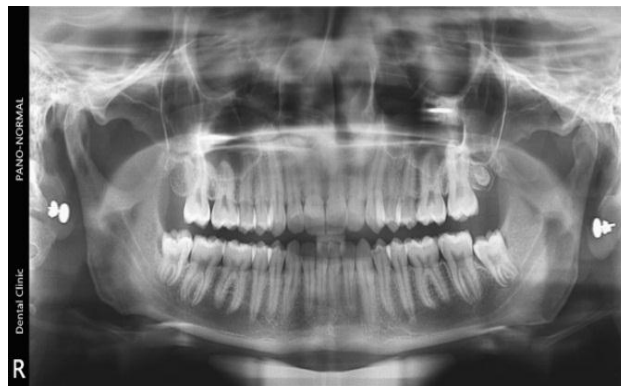

Fig. 8: Orthopantomogram of patient

Discussion

The etiology of TMD is multifactorial, and it involves an alteration in the functional balance between the fundamental elements of the stomatognathic system: dental occlusion, jaw muscles and TMJ. Costen was one of the first to established with certainty the involvement of occlusion in the development of TMD. Rammelsberg offered a review of the etiopathogenic model of TMD development wherein high abrasion and insufficient restorative procedure on posterior teeth are risk factors causing occlusal instability.⁶ Teeth clenching and bruxism have been extensively studied as possible risk factors for TMD as well. The Occlusal Vertical Dimension (OVD) for dentate individual is mainly determined by the remaining dentition, hence loss of tooth substance might influence the OVD. A loss of OVD can significantly affect patient function, comfort and aesthetics and to some extent have an effect on the TMJ.⁷ Various treatment options are currently available to treat patients with TMD, ranging from conservative methods to more invasive procedures. There is considerable evidence to support conservative management therapies of TMD such as occlusal appliances, behavioural therapy, physiotherapy and jaw exercises.^{8,9} An increase in OVD can be carried out conservatively with occlusal appliances.^{10,11} Occlusal appliances have a dual purpose, they stabilize the TMJ as well as increase the OVD. On the basis of patient adaptation to the occlusal appliance, permanent restorations at the increased vertical dimension can then be fabricated¹²

Conclusion

Diagnosing a cases of temporomandibular joint disorder is challenging yet once diagnosed it can be completely cured. The pain is present in the muscles and condyle head. Construction of a relaxation splint restores the normal functioning of the muscle and provides relief from pain due to relief of the pain.

Conflict of Interest: None.

References

1. Wright. "Management and Treatment of Temporomandibular Disorders: A Clinical Perspective". *J Man Manip Ther* 17.4 (2009):247-254.

2. Ferreira. "Ear Acupuncture Therapy for Masticatory Myofascial and Temporomandibular Pain: A Controlled Clinical Trial". *Evid Based Complementary and Alternat Med* 2015;1-9.
3. Kaur. "Prosthodontic Management of Temporomandibular Disorders". *J Indian Prosthodont Soc* 13.4 (2012):400-405.
4. Koh. "Occlusal adjustment for treating and preventing temporomandibular joint disorders". *Cochrane Database Syst Rev* 2016.
5. Tsukiyama. "An Evidence-based Assessment of Occlusal Adjustment as a Treatment for Temporomandibular Disorders". *J Prosthetic Dent* 86.1 (2001):57-66.
6. Rammelsberg P. "Untersuchungen über Ätiologie, diagnose und Therapie von Diskopathien des Kiefergelenkes". Berlin: Quintessenz; 1998
7. Turner KA and Missirlian DM. "Restoration of the extremely worn dentition". *J Prosthetic Dent* 52.4 (1984):467-474.
8. List T. "Pharmacologic interventions in the treatment of temporomandibular disorders, atypical facial pain, and burning mouth syndrome. A qualitative systematic review". *J Orofacial Pain* 17.4 (2003):301-310.
9. Carlsson GE. "Critical review of some dogmas in prosthodontics". *J Prosthodont Res* 53.1 (2009):3-10.
10. De Boever JA. "Need for occlusal therapy and prosthodontic treatment in the management of temporomandibular disorders. Part I. Occlusal interferences and occlusal adjustment". *J Oral Rehabil* 27.5 (2000):367- 379.
11. Dao TT and Lavigne GJ. "Oral splints: the crutches for temporomandibular disorders and bruxism? ". *Crit Rev Oral Biol Med* 9.3 (1998):345-361.
12. De Boever JA. "Need for occlusal therapy and prosthodontic treatment in the management of temporomandibular disorders. Part II: Tooth loss and prosthodontic treatment". *J Oral Rehabil* 27.8 (2000):647-665.

How to cite this article: Hassan SA, Bhateja S, Aggarwal N, Arora G, Temporomandibular joint disorders: A case series. *J Surg Allied Sci* 2019;1(1):28-31.